



ISTITUTO PER LO STUDIO
E LA PREVENZIONE ONCOLOGICA



La citologia negli screening oncologici

Le lesioni ghiandolari: inquadramento morfologico e criticità

Roma, 19 Novembre 2014


Centro Formazione

Ordine Nazionale dei Biologi

Viale della Piramide Cestia, 1

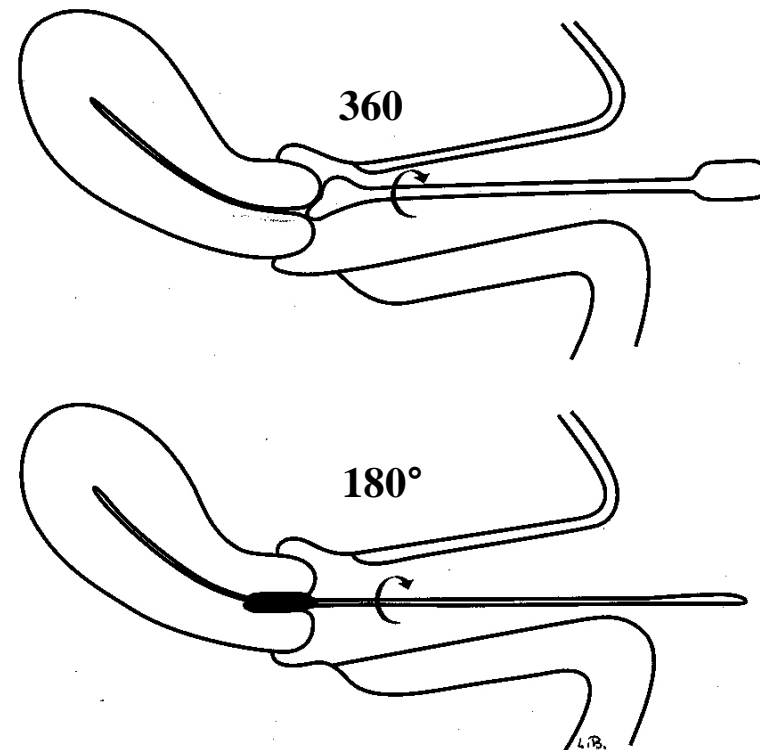
Dr.ssa Marzia Matucci

Pap-Test: prelievo



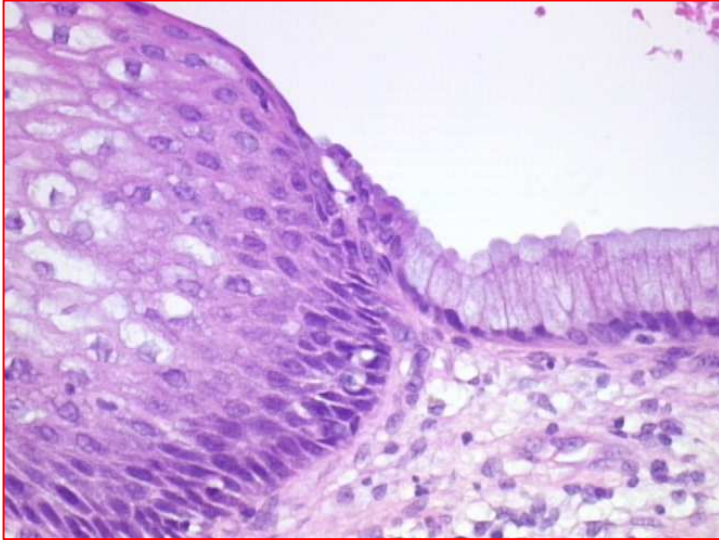
Effettuato con:
Spatola di Ayre

Cytobrush

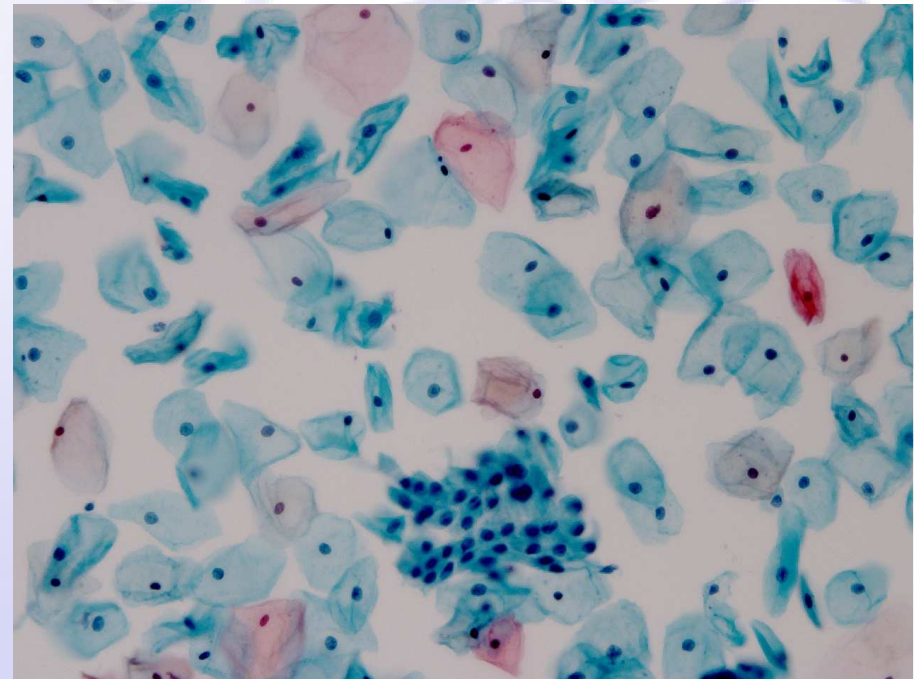


Prelievo

Giunzione squamo-colonnare



Rappresenta una netta linea di demarcazione tra l'epitelio squamoso maturo dell'esocervice e l'epitelio cilindrico monostratificato dell'endocervice. Il passaggio è netto, a "colpo d'ascia".

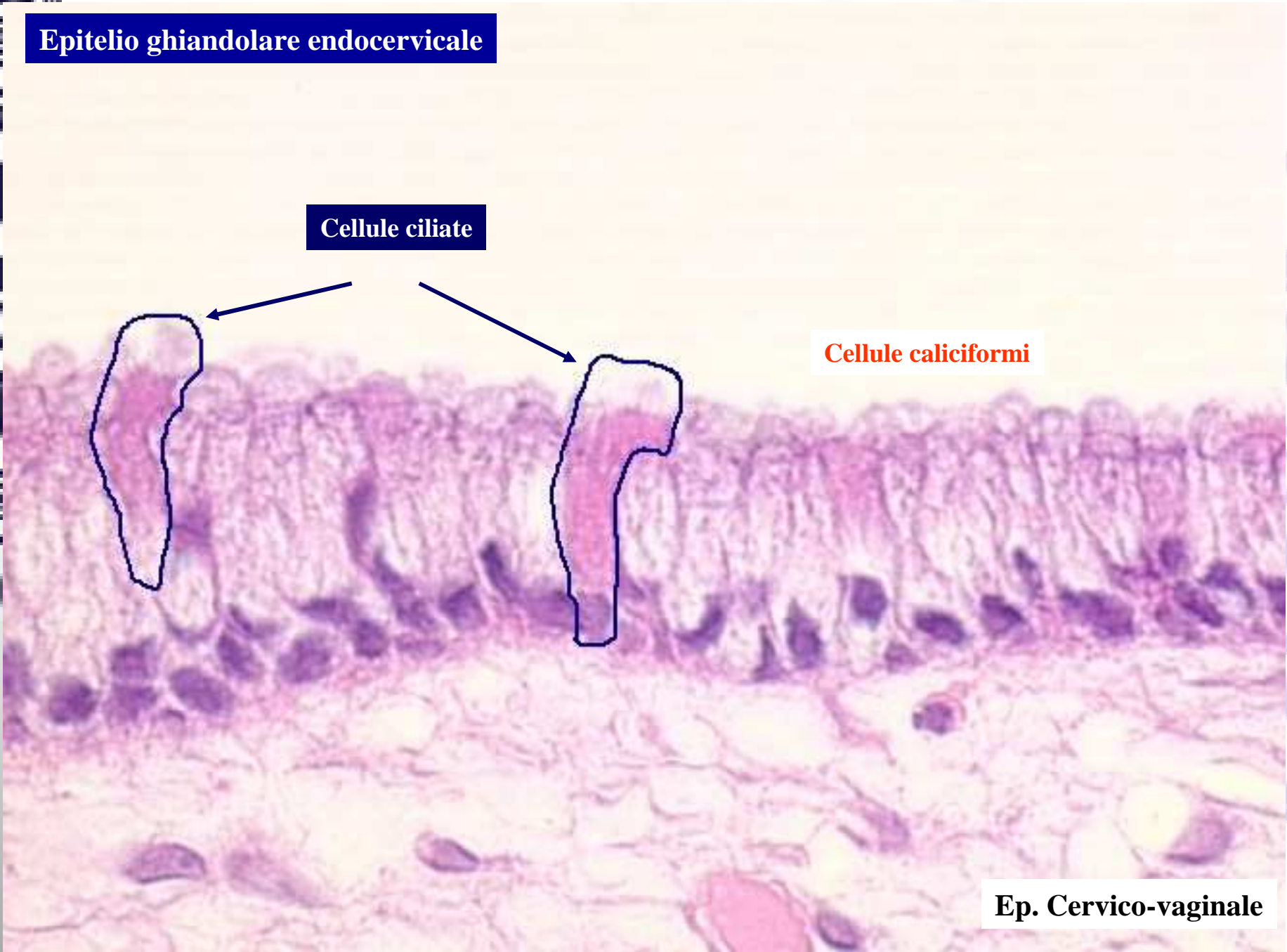


Epitelio ghiandolare endocervicale

Cellule ciliate

Cellule caliciformi

Ep. Cervico-vaginale

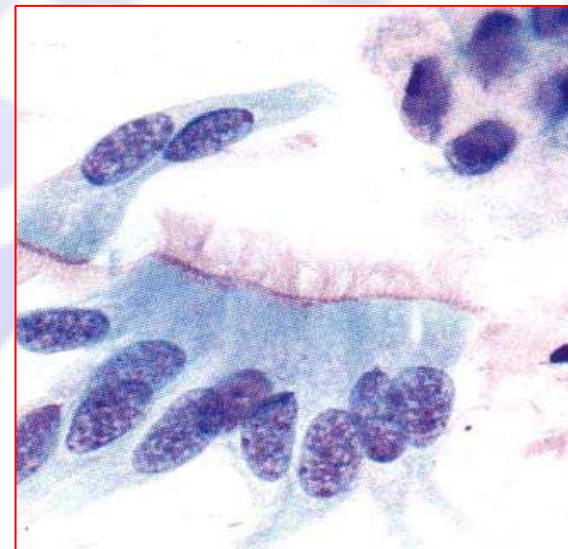
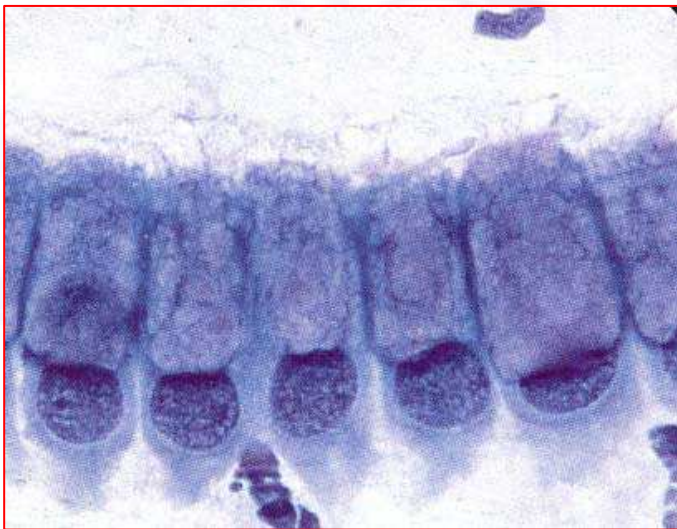
Cellule secretorie

- Citoplasma abbondante
- Multipli o singoli grandi vacuoli
- Presenti in gravidanza, uso di pillole contraccettive, polipi endocervicali

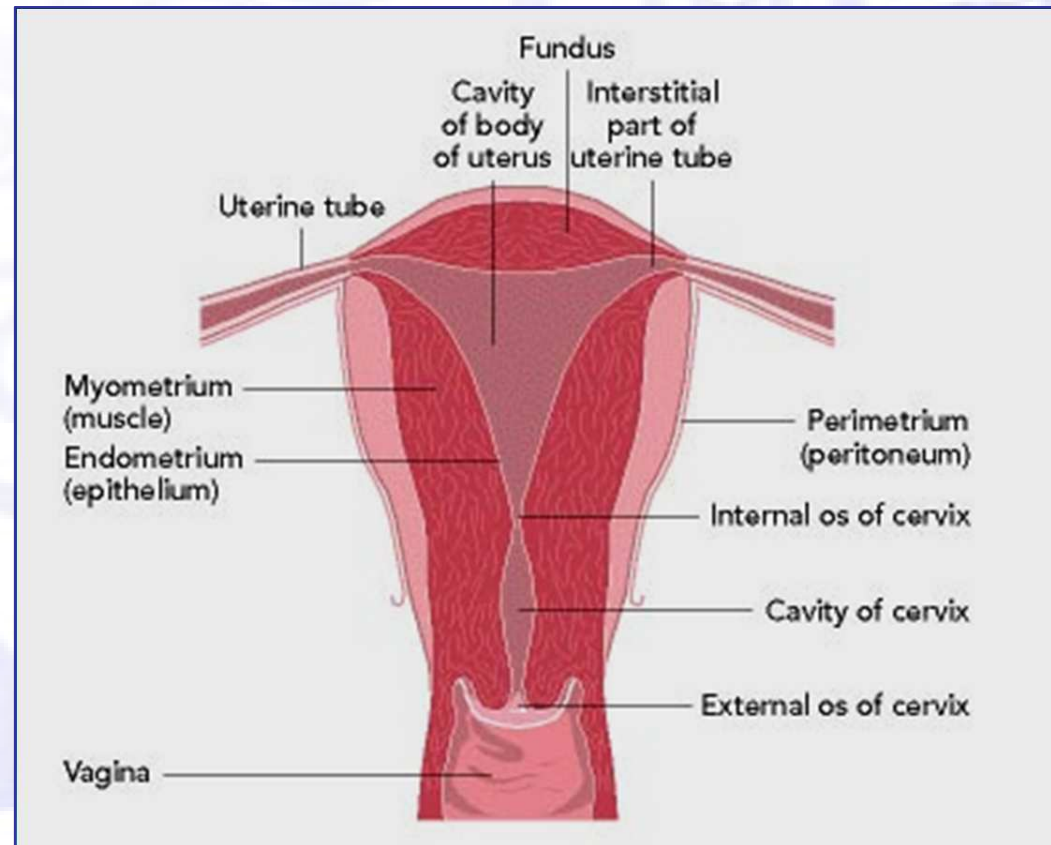
Cellule ciliate

- Citoplasma più denso di quelle secretorie
- Terminal bar, ciglia
- Meno comunemente presenti rispetto alle secretorie
- Presenti nella prima metà del ciclo mestruale (fase estrogenica)
- Possibile ruolo nella propulsione del muco



Cellule ghiandolari presenti nello striscio cervicale

- Endocervicali
- Endometriali



Cellule ghiandolari

Diagnosi differenziale

Cellule endocervicali

- Grandi
- Dimensioni variabili
- Disposizione bidimensionale
- Lembi a nido d'ape/palizzate
- Bi/multinucleazione
- Cromatina fine, pallida
- Citoplasma abbondante
- Migliore conservazione

Cellule endometriali

- Piccole
- Più uniformi
- Cluster affollati tridimensionali
- Doppio contorno
- Multinucleazioni rare
- Cromatina grossolana scura
- Citoplasma scarso
- Degenerate



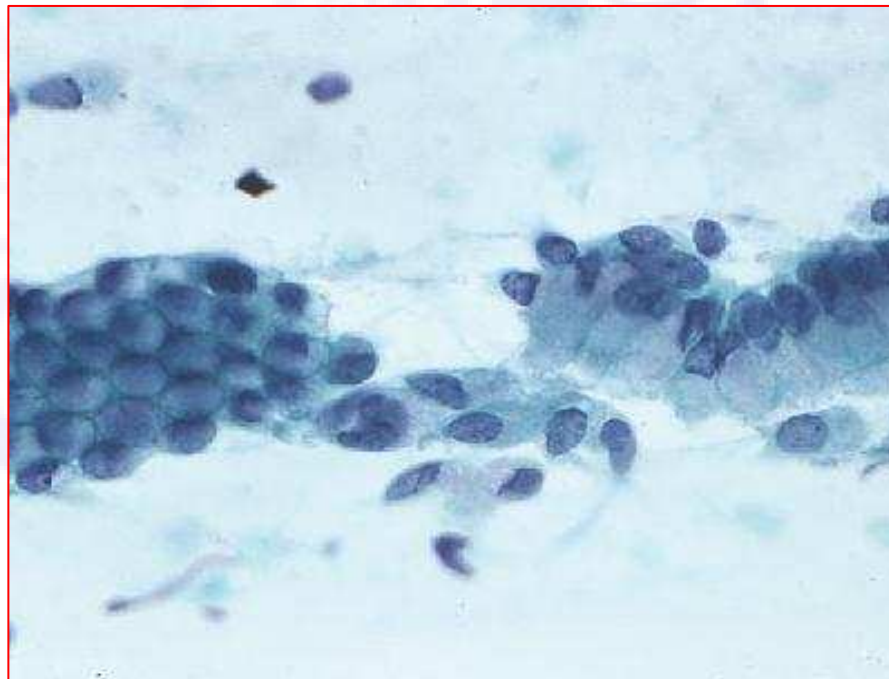
CELLULE ENDOCERVICALI

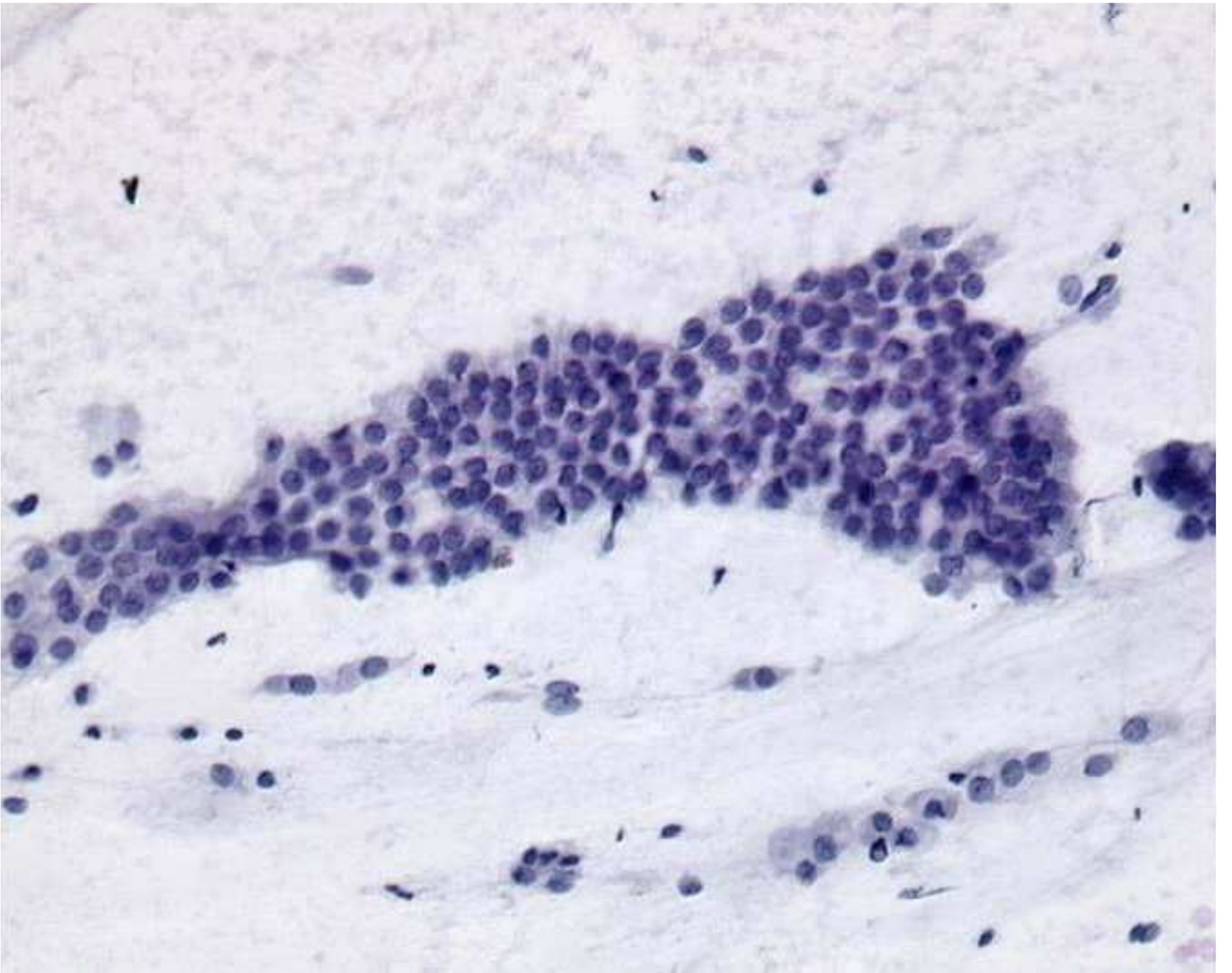
quadri morfologici negativi

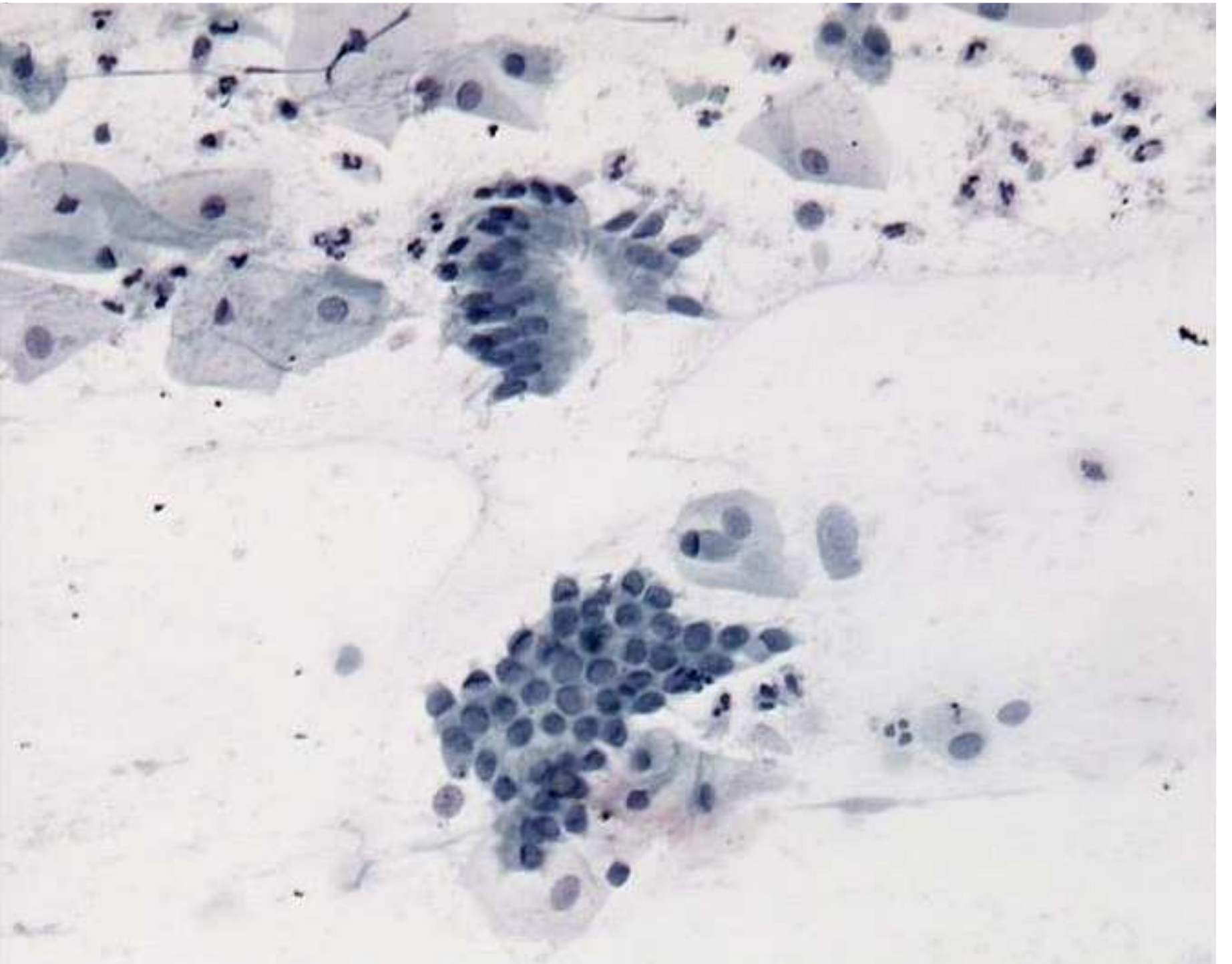
Architettura delle cellule endocervicali

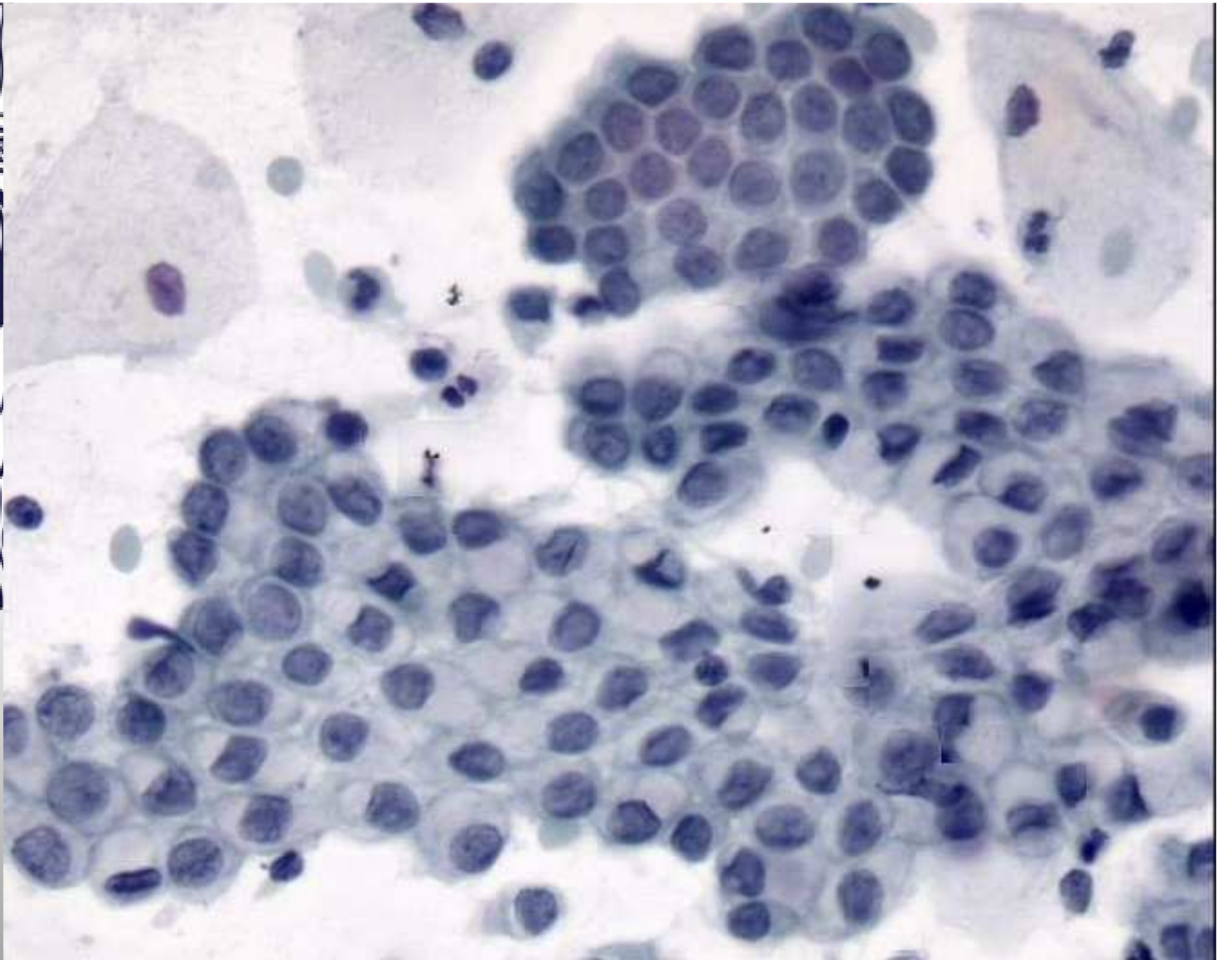
- ✓ Cellule singole
- Colonnari con nuclei basali e citoplasma apicale

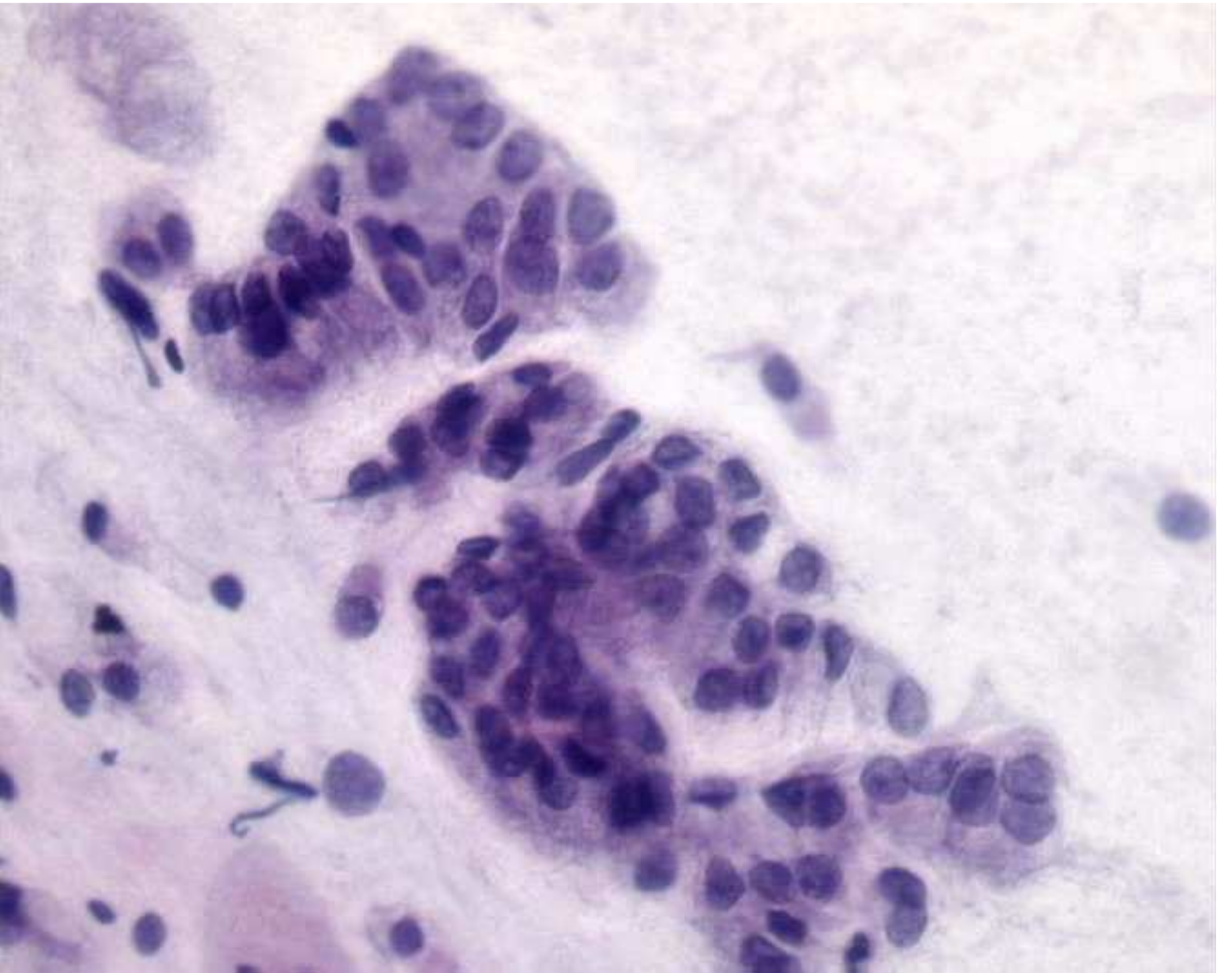
- ✓ Lembi
- Cellule uniformi ordinate a palizzata
- Nido d'ape con lieve prominenza della membrana nucleare

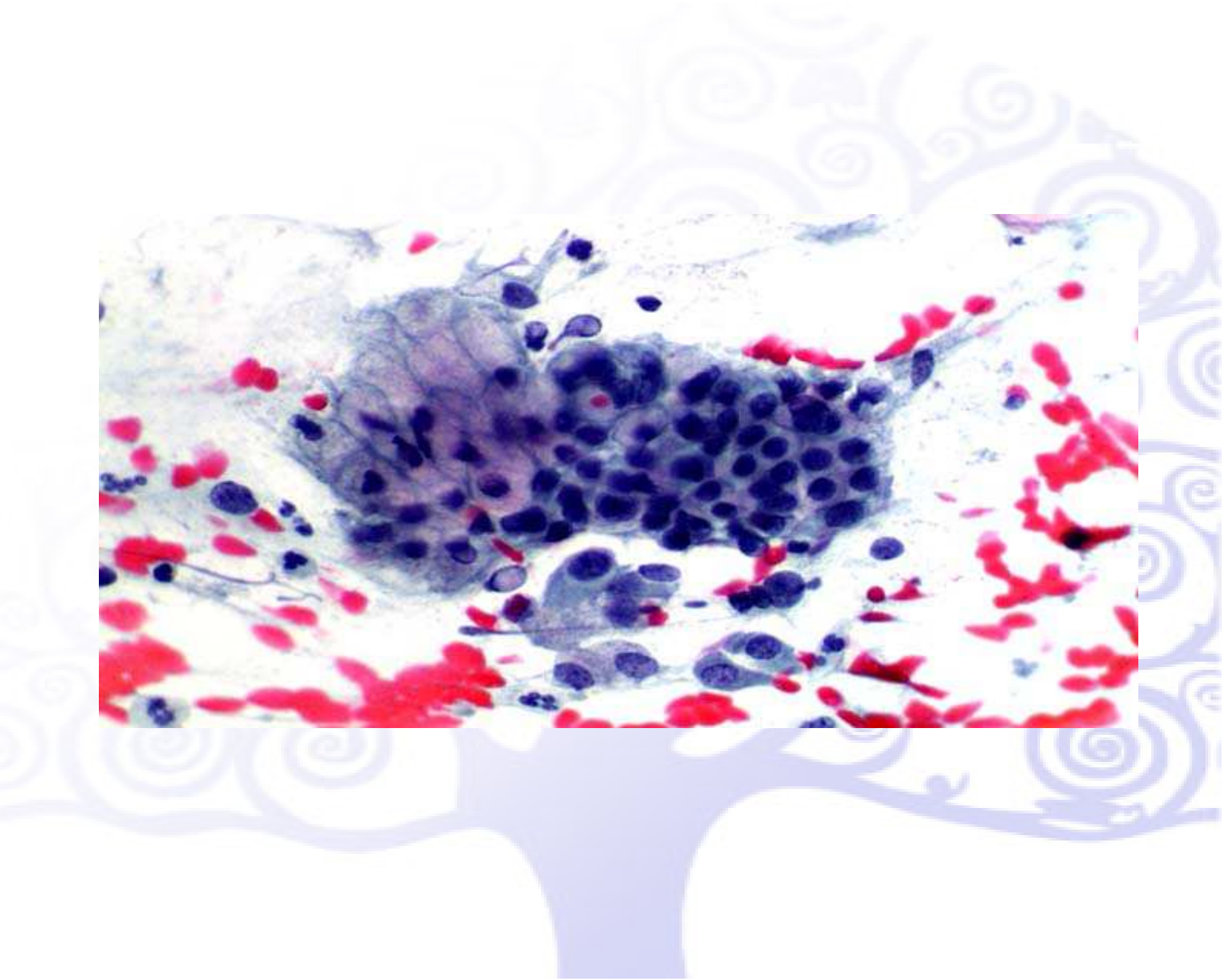
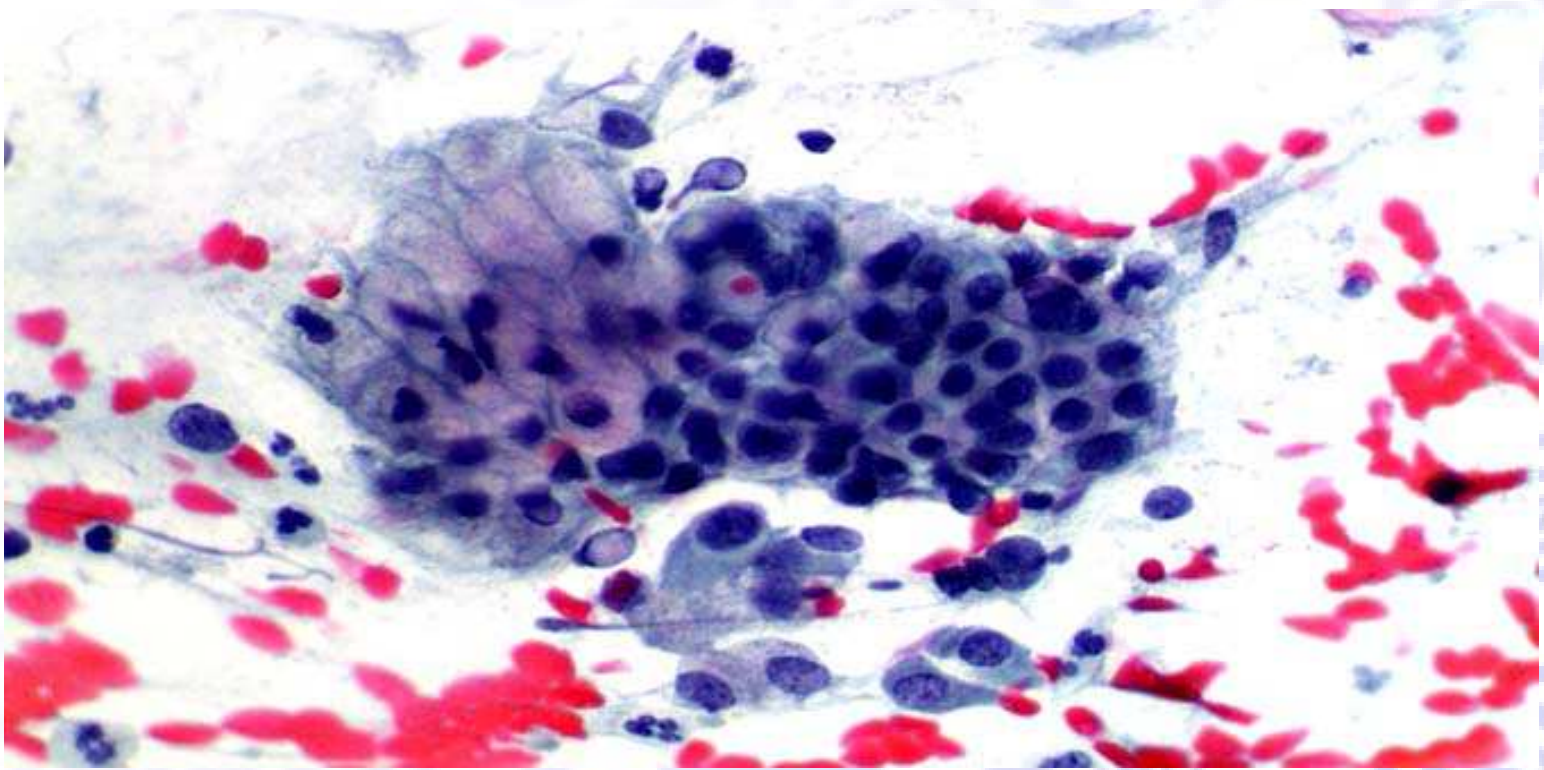


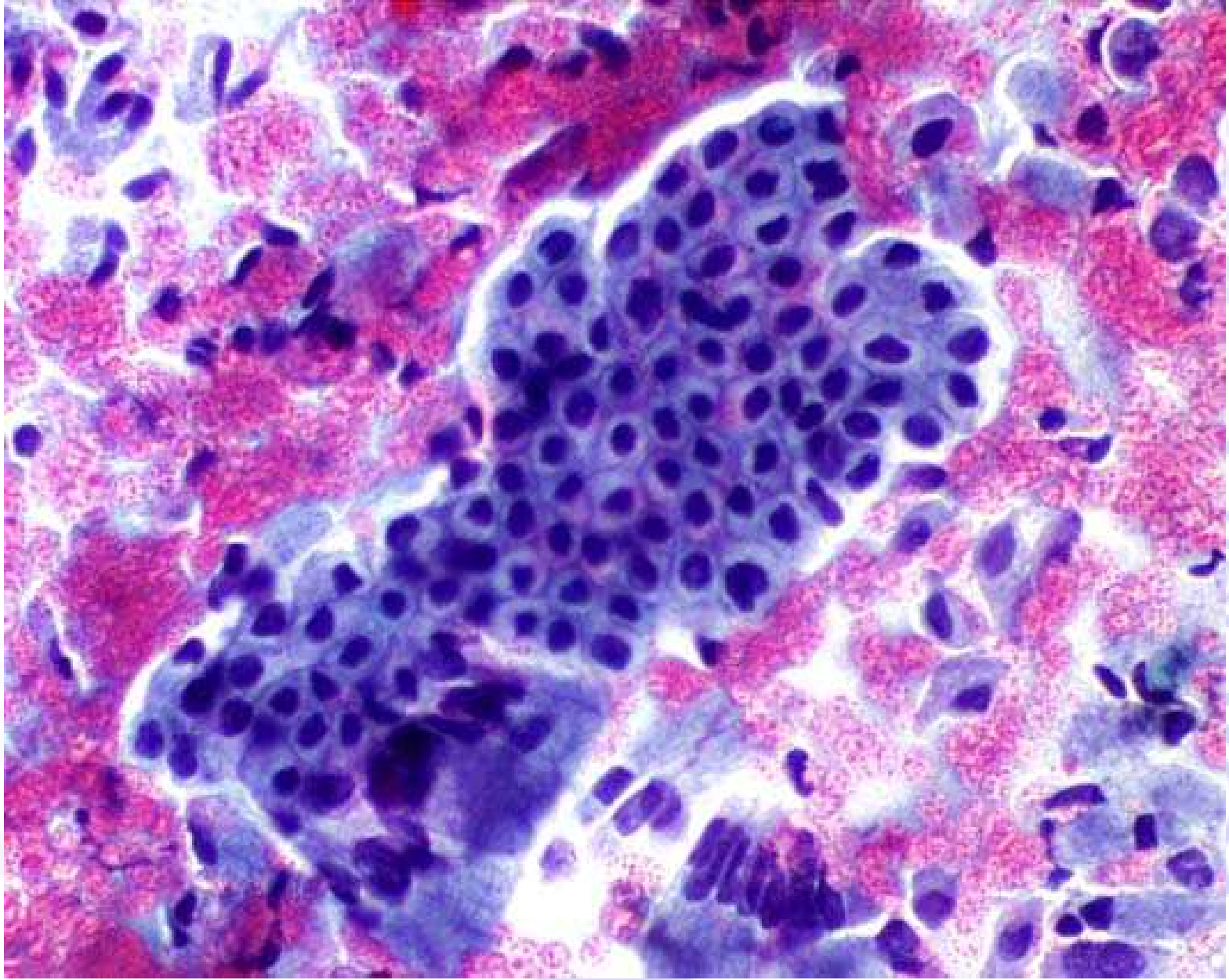














CELLULE ENDOMETRIALI

quadri morfologici negativi

Cellule Endometriali

Reperto occasionale

- Brush endocervicale energico (spinto nella parte infer. cavità uterina)
- Prima metà del ciclo (fino al 14° giorno)
- Dopo il 25° giorno del ciclo.
- Durante le mestruazioni
- Donne in post-menopausa

* Endometriosi

* HRT

* IUD

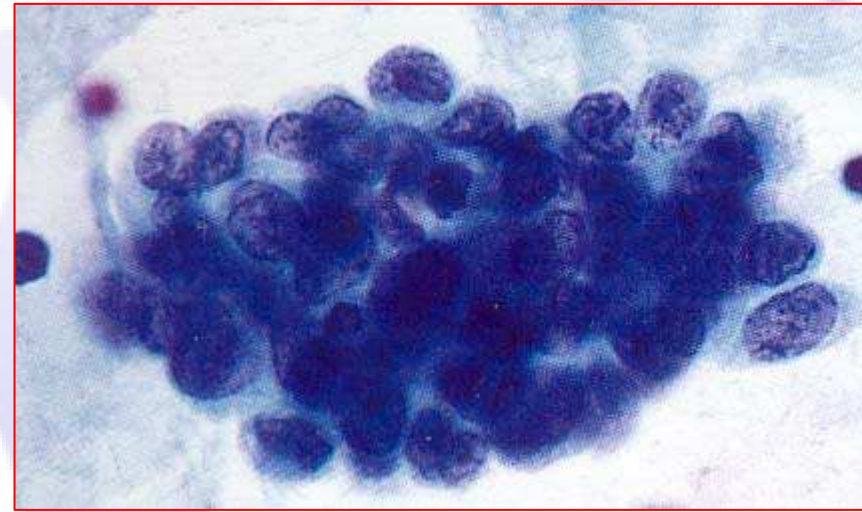
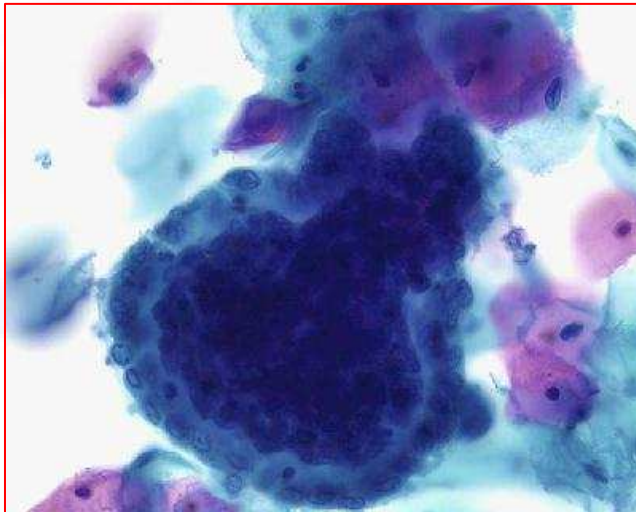
* Postpartum

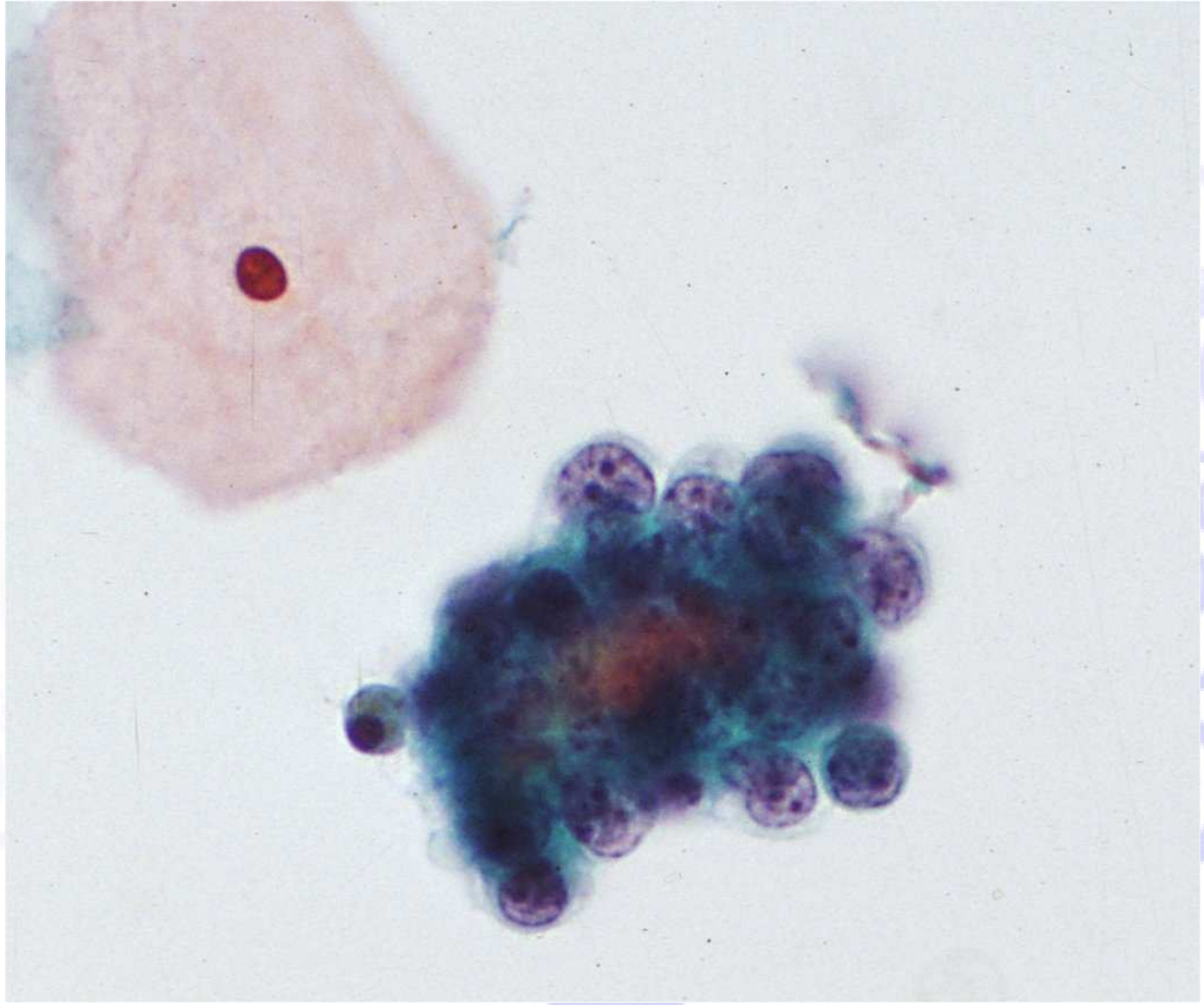
* Iperplasia endometriale

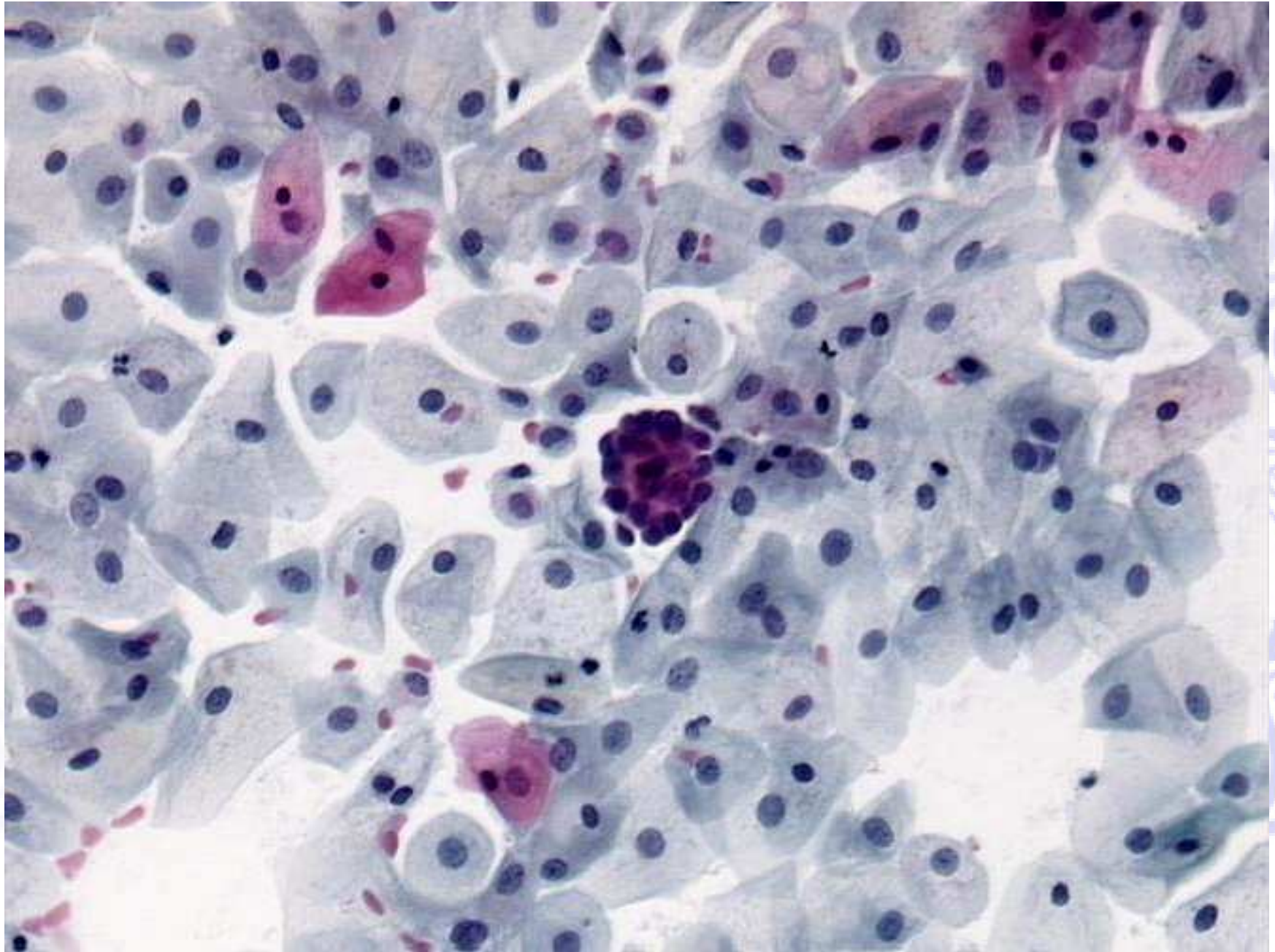
* Neoplasia endometriale

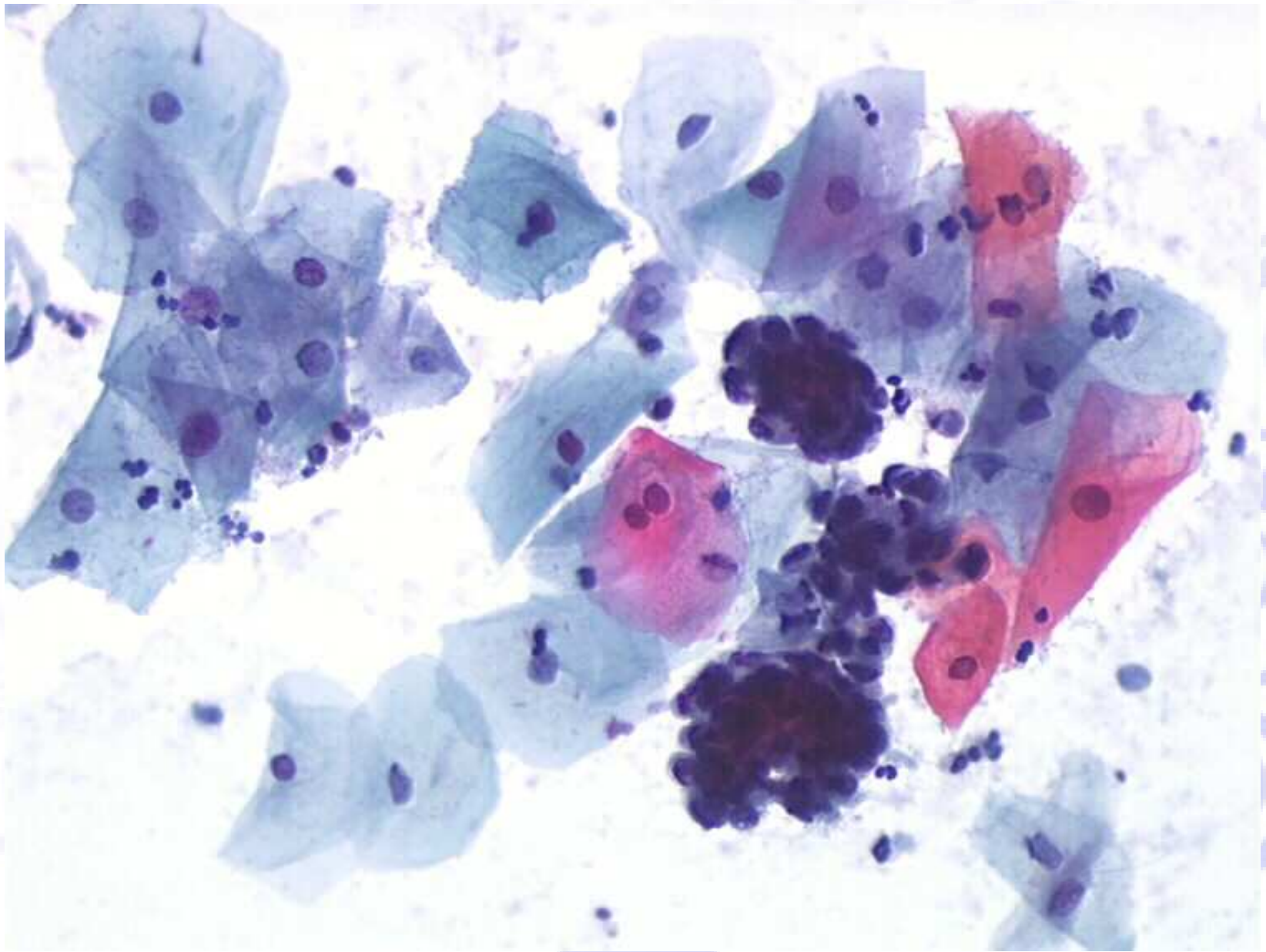
Architettura delle cellule endometriali

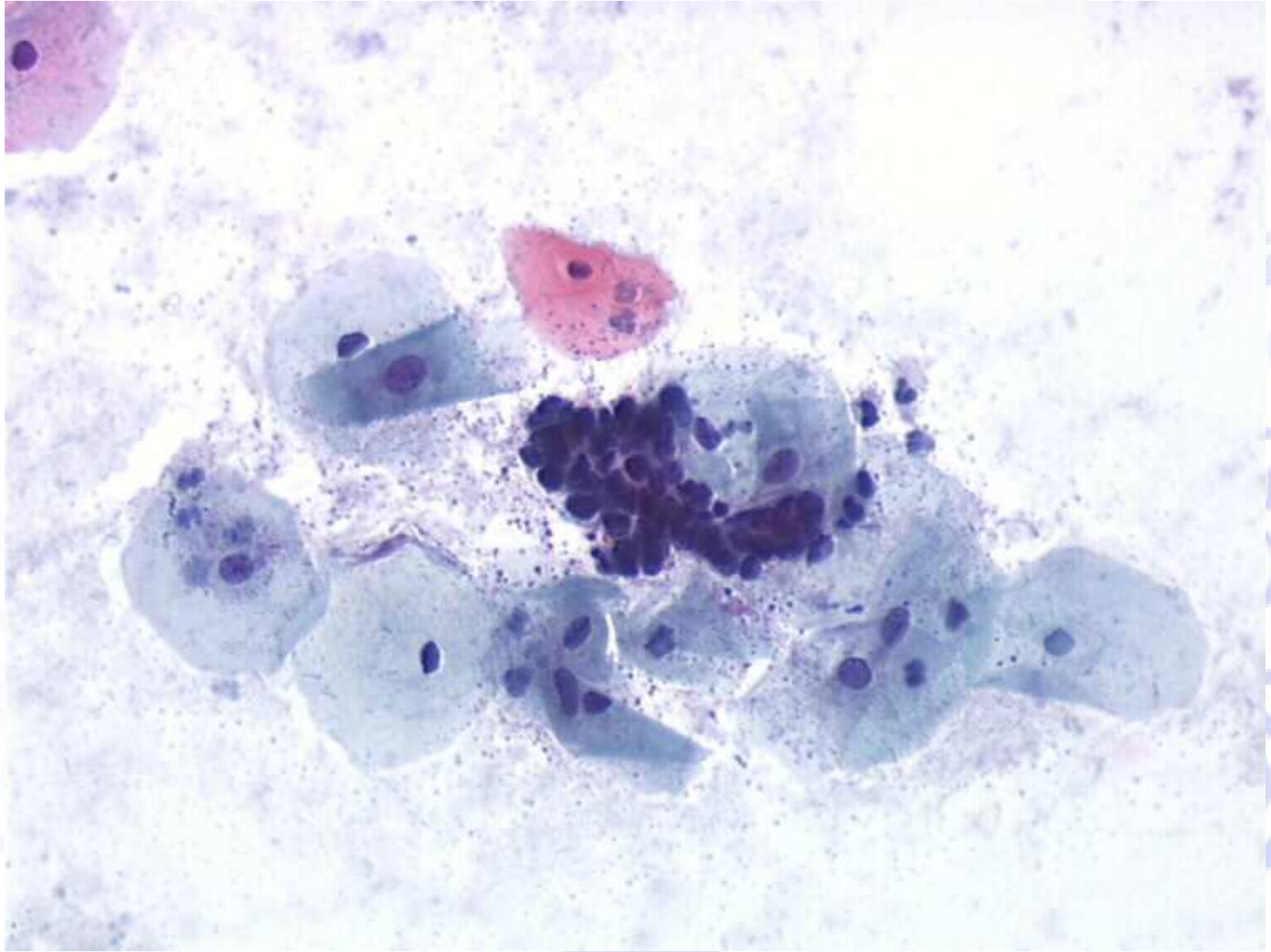
- ❖ Gruppi tridimensionali affollati; palle di cellule con un “doppio contorno” (exodus) con una colorazione interna più scura (stroma) e una colorazione più leggera dell’epitelio esterno.
- ❖ Ammassi tridimensionali di cellule ghiandolari senza stroma centrale. Le cellule sono piccole e i nuclei degenerati e ipercromatici

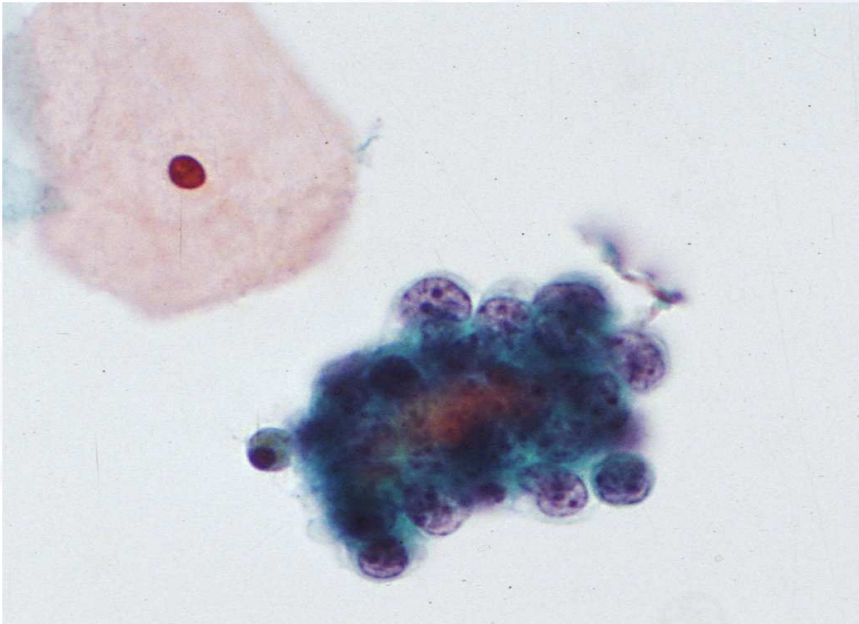
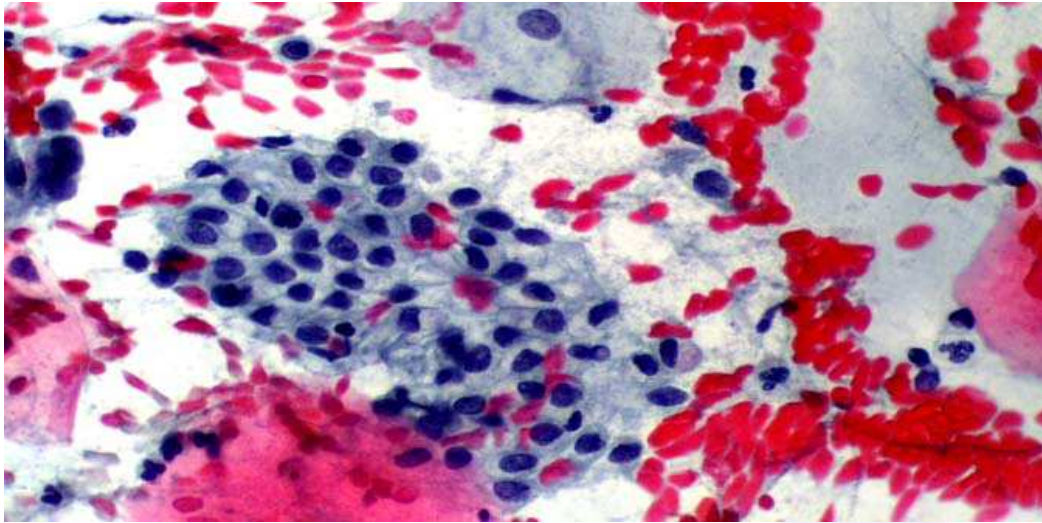




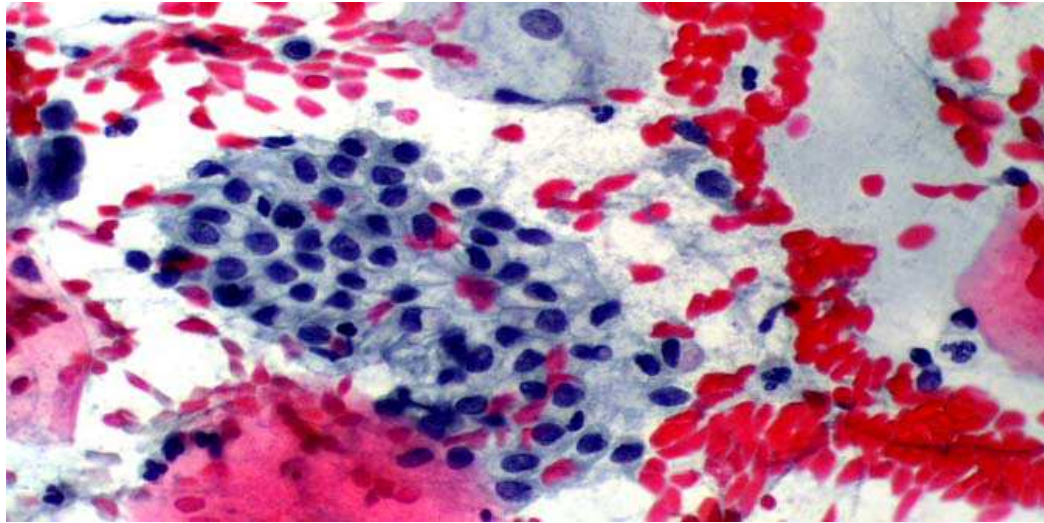




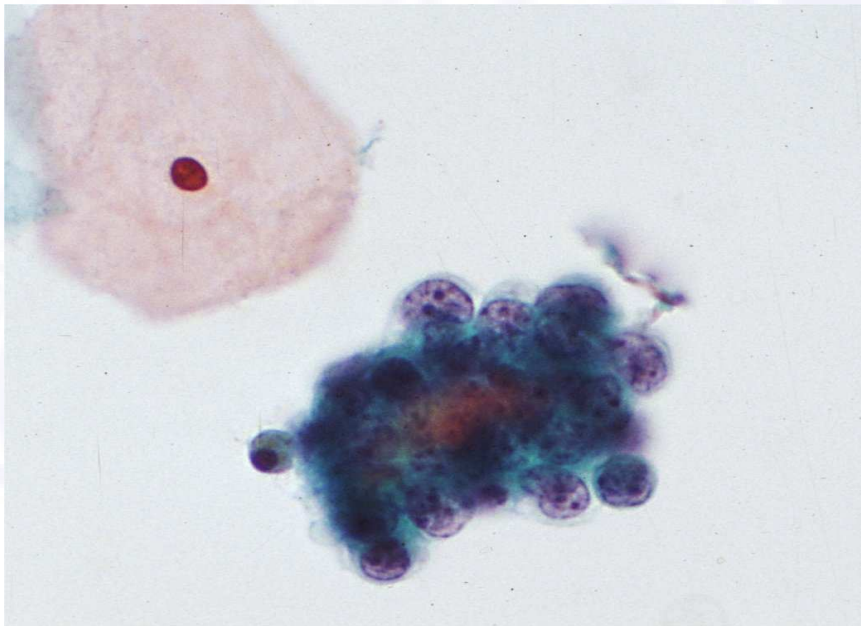




Quiz



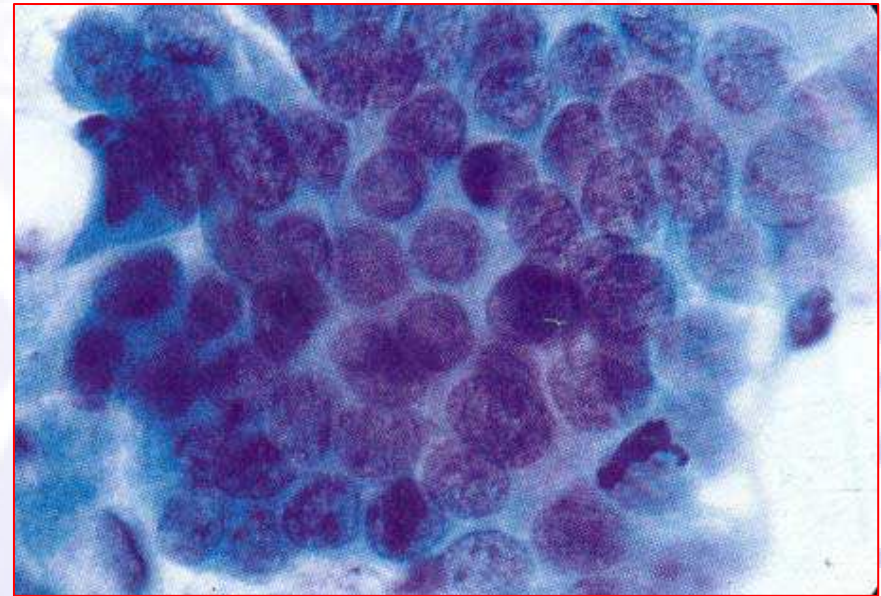
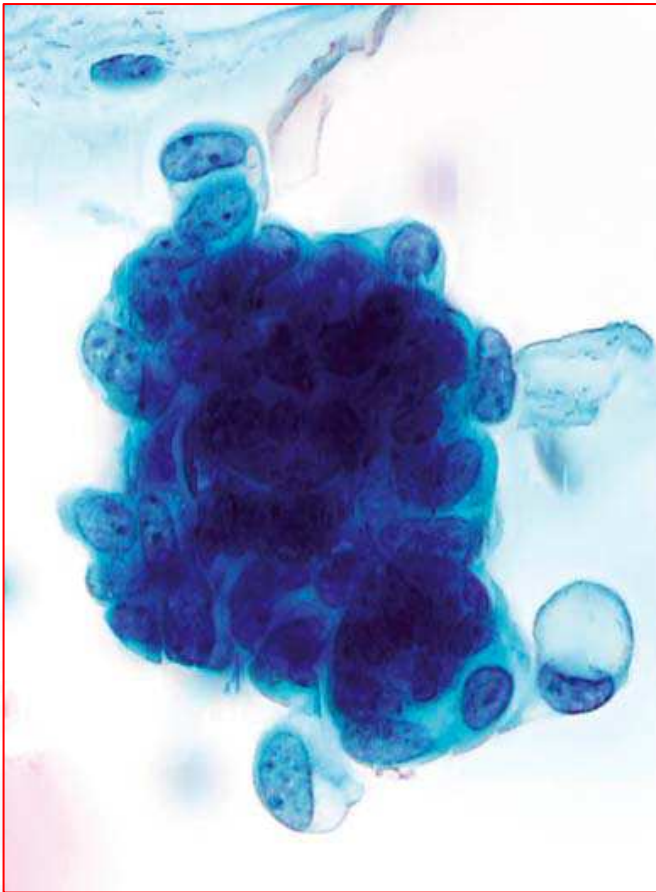
Cellule
endocervicali



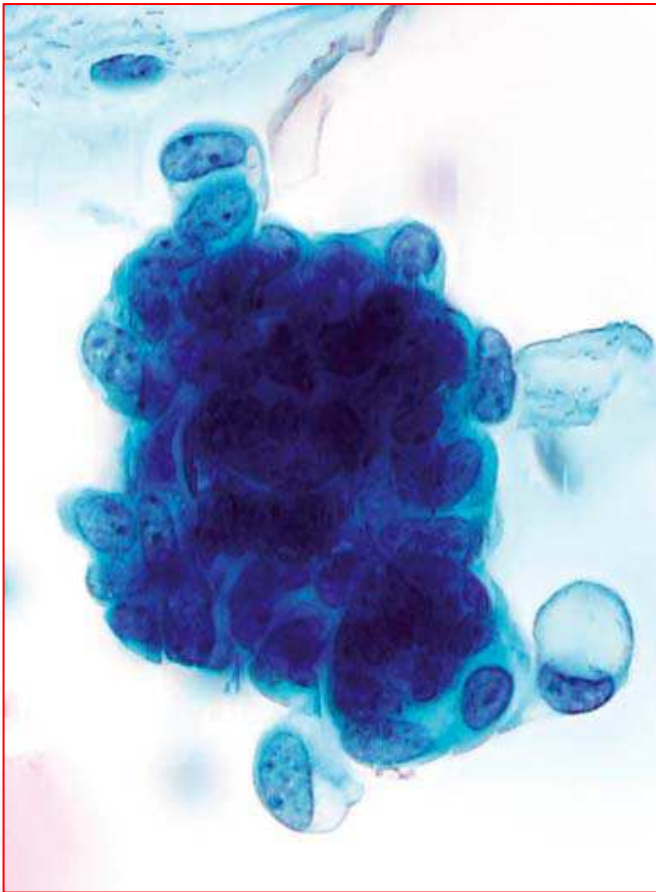
Cellule
endometriali

Quiz

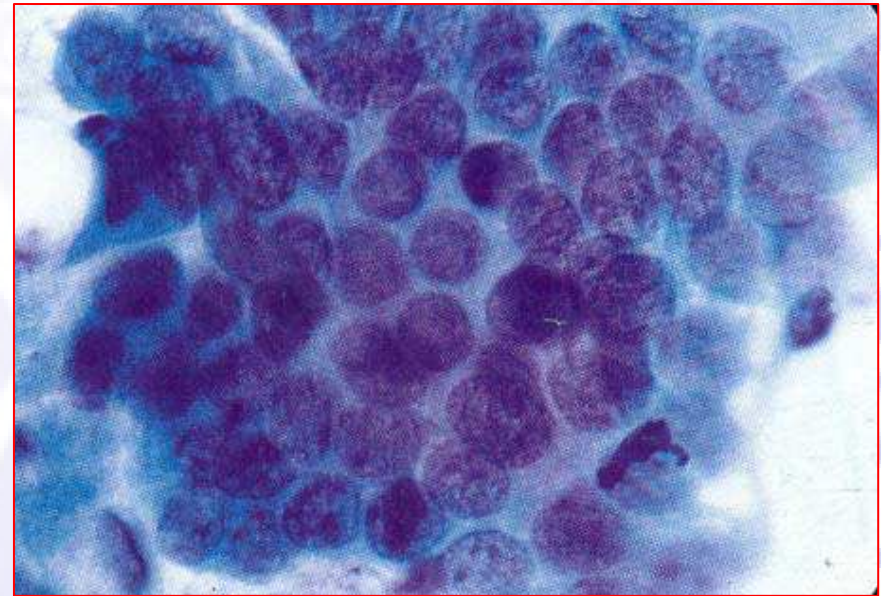
Quiz



Quiz



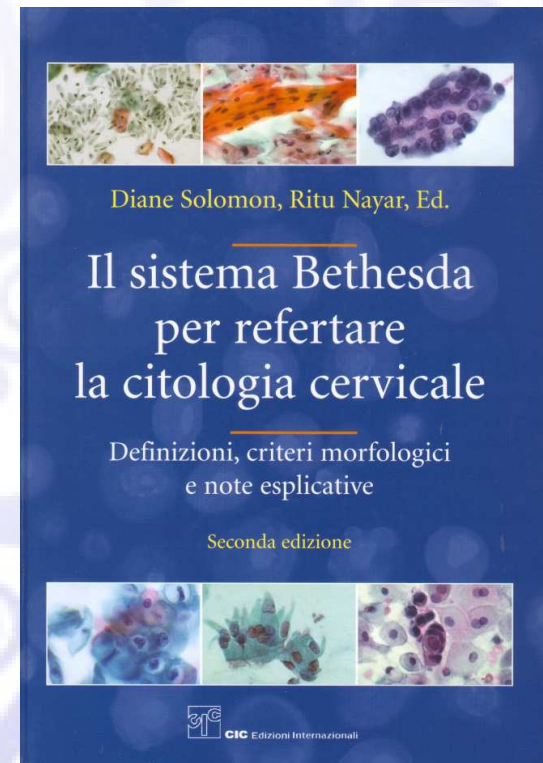
Cellule endometriali



Cellule endocervicali

Anomalie delle cellule ghiandolari

- **Atipiche**
 1. Endocervicali (NAS)
 2. Endometriali (NAS)
 3. Ghiandolari non altrimenti specificate (NAS)
- **Atipiche**
 1. Endocervicali, probabile neoplasia
 2. Ghiandolari, probabile neoplasia
- **Adenocarcinoma endocervicale in situ**
- **Adenocarcinoma**
 1. Endocervicale
 2. Endometriale
 3. Extra-uterino
 4. Non altrimenti specificato

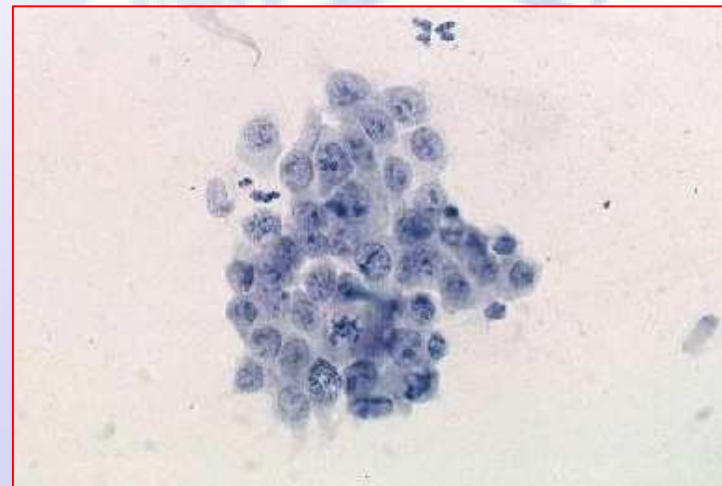


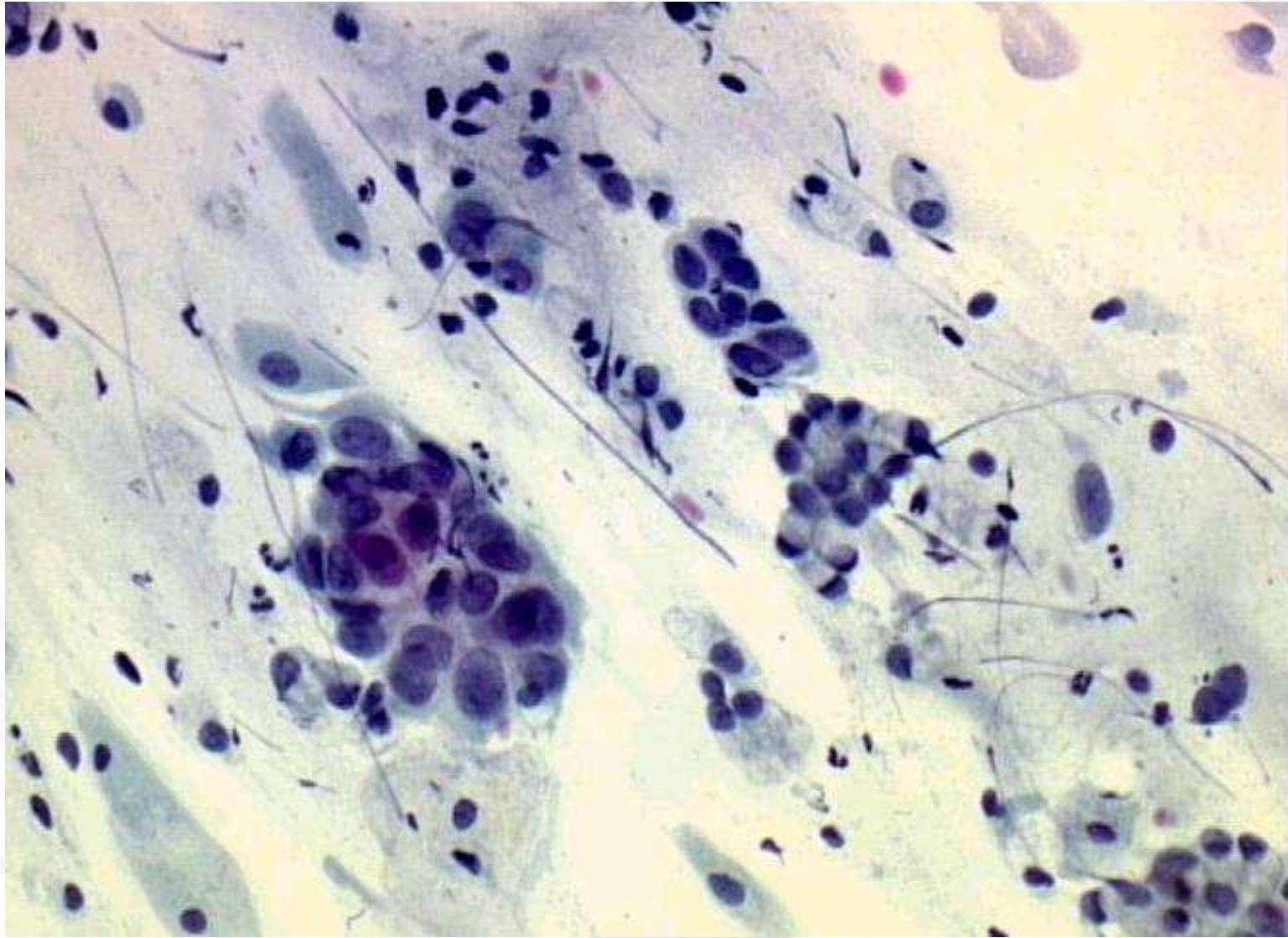
Cellule endocervicali atipiche

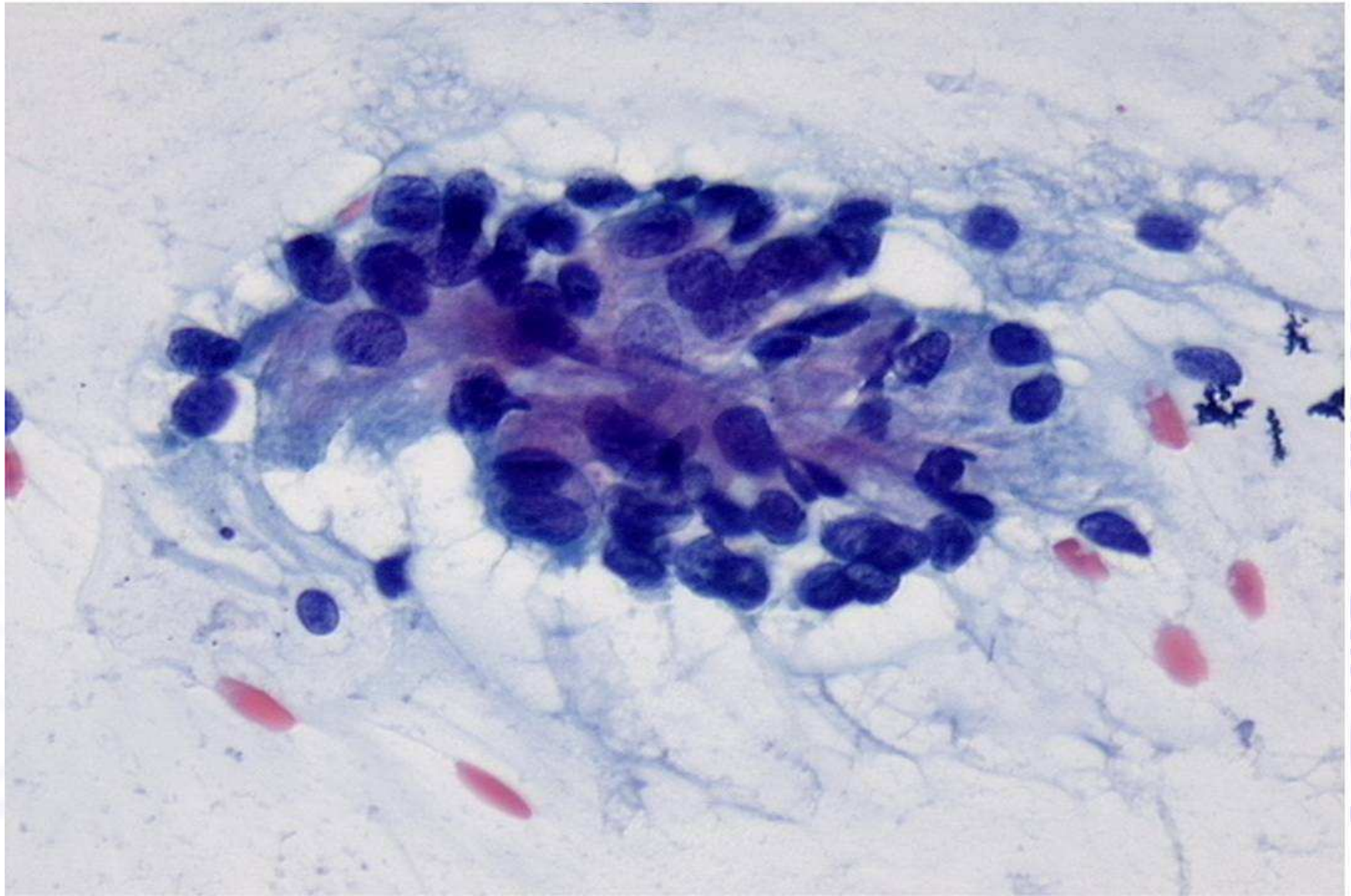
Criteri morfologici:

- Cellule disposte in lembi o a nastro con addensamento cellulare e sovrapposizione nucleare
- Citoplasma abbondante, rapporto nucleo/citoplasma (N/C) aumentato
- Bordi cellulari distinti
- Ingrandimento nucleare fino a 3-5 volte un nucleo endocervicale normale
- Variazione di dimensione e forma nucleare
- Modesta ipercromasia
- Possono essere presenti nucleoli
- Mitosi rare

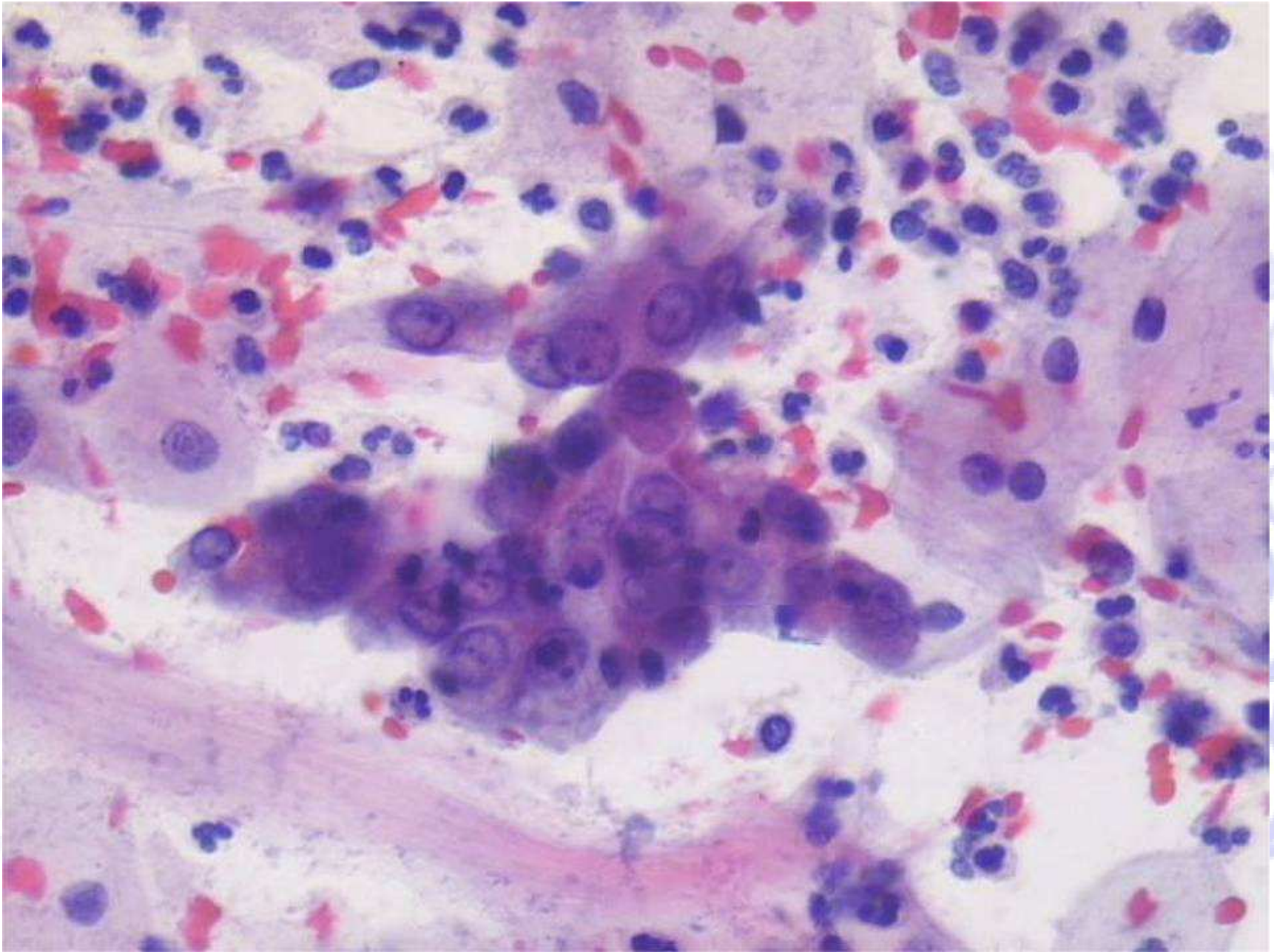
(TBS 2001)

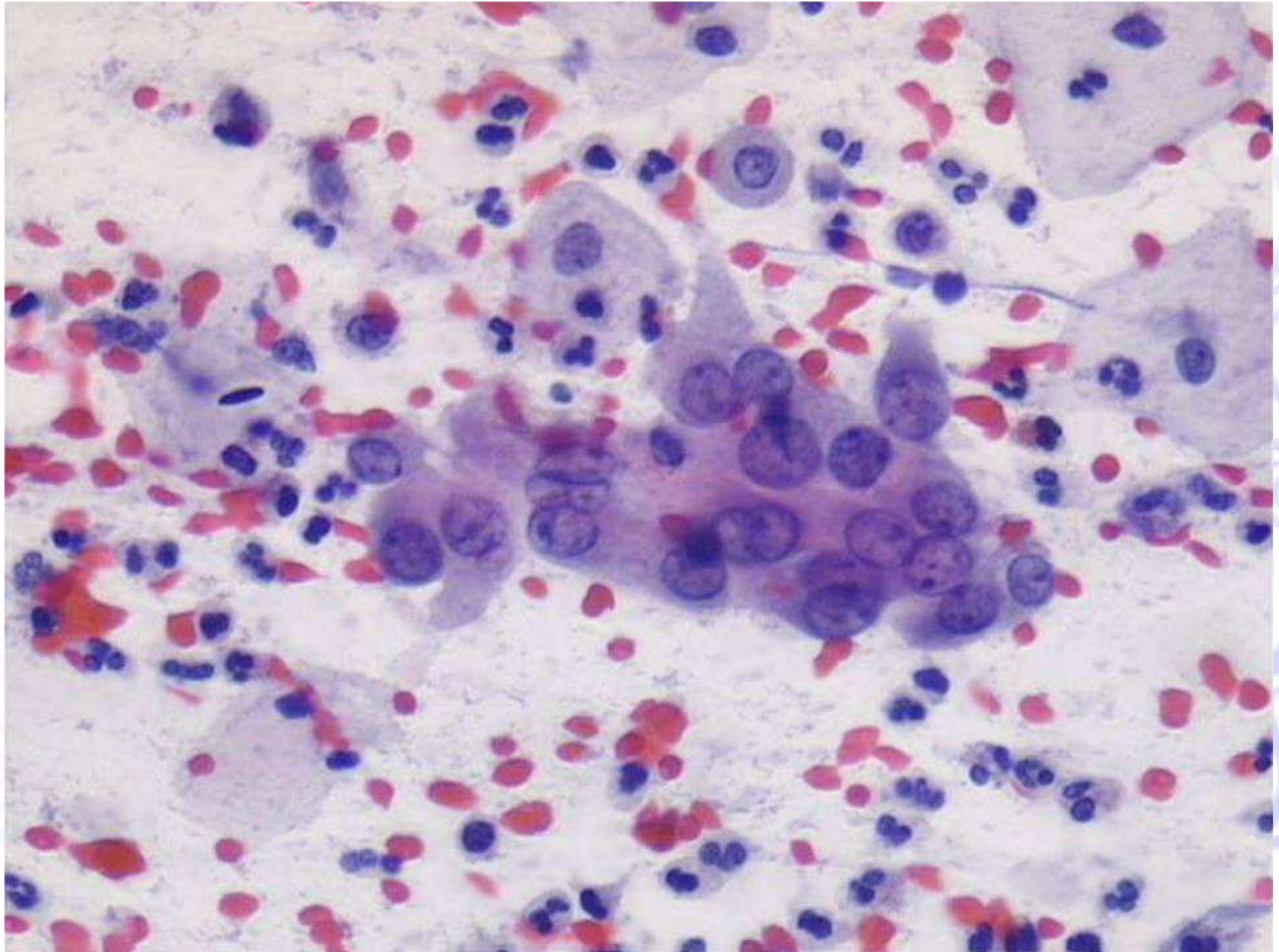


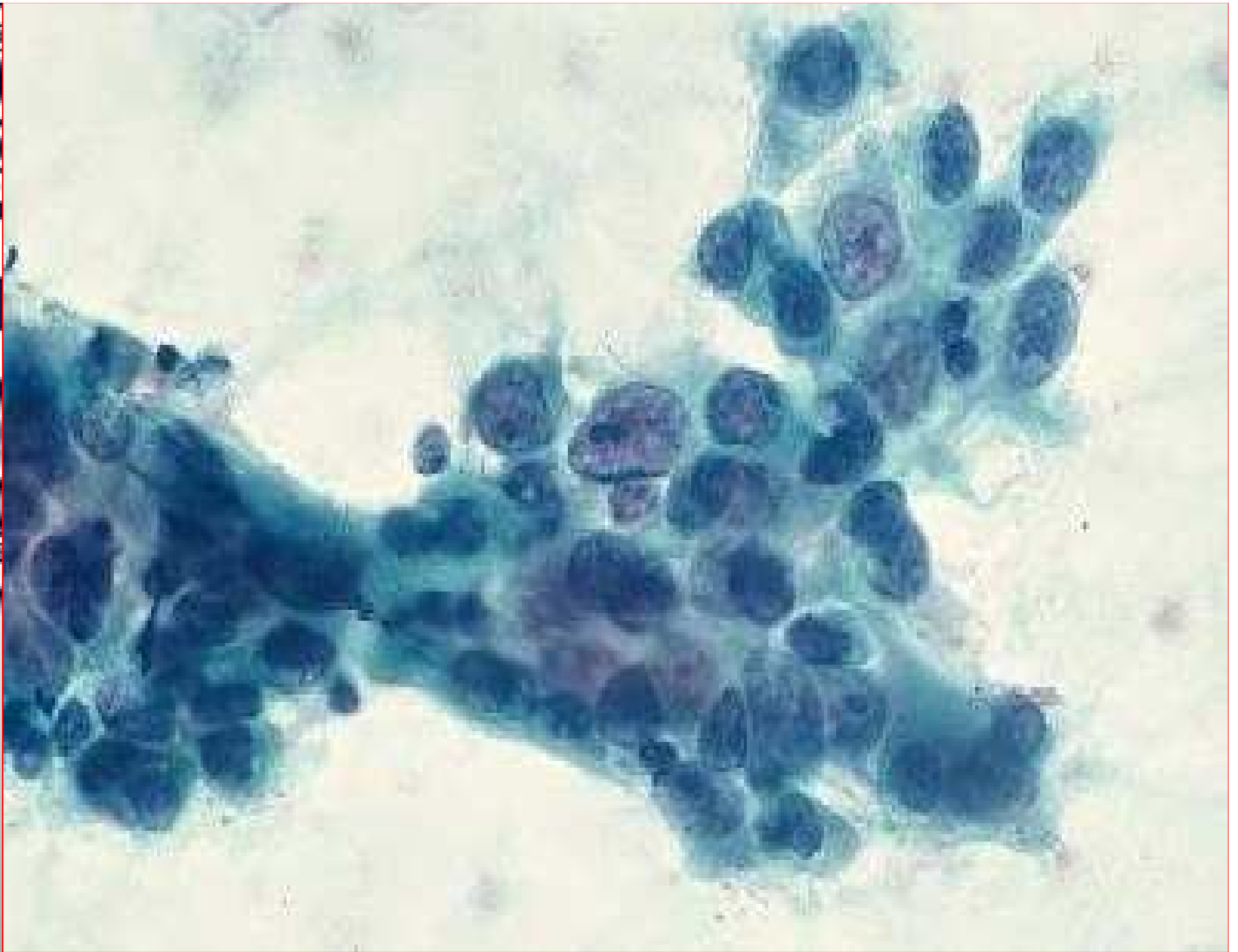


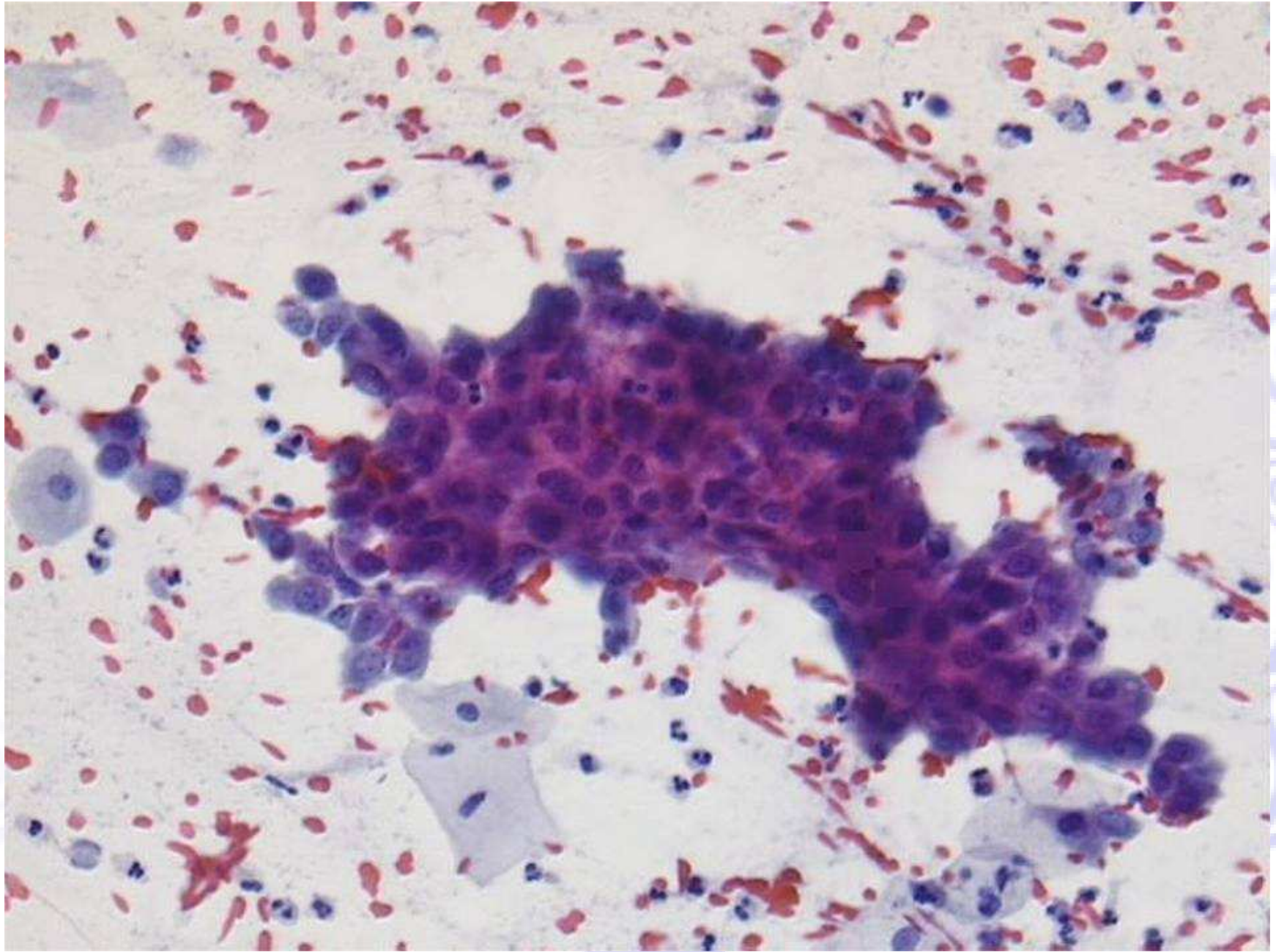


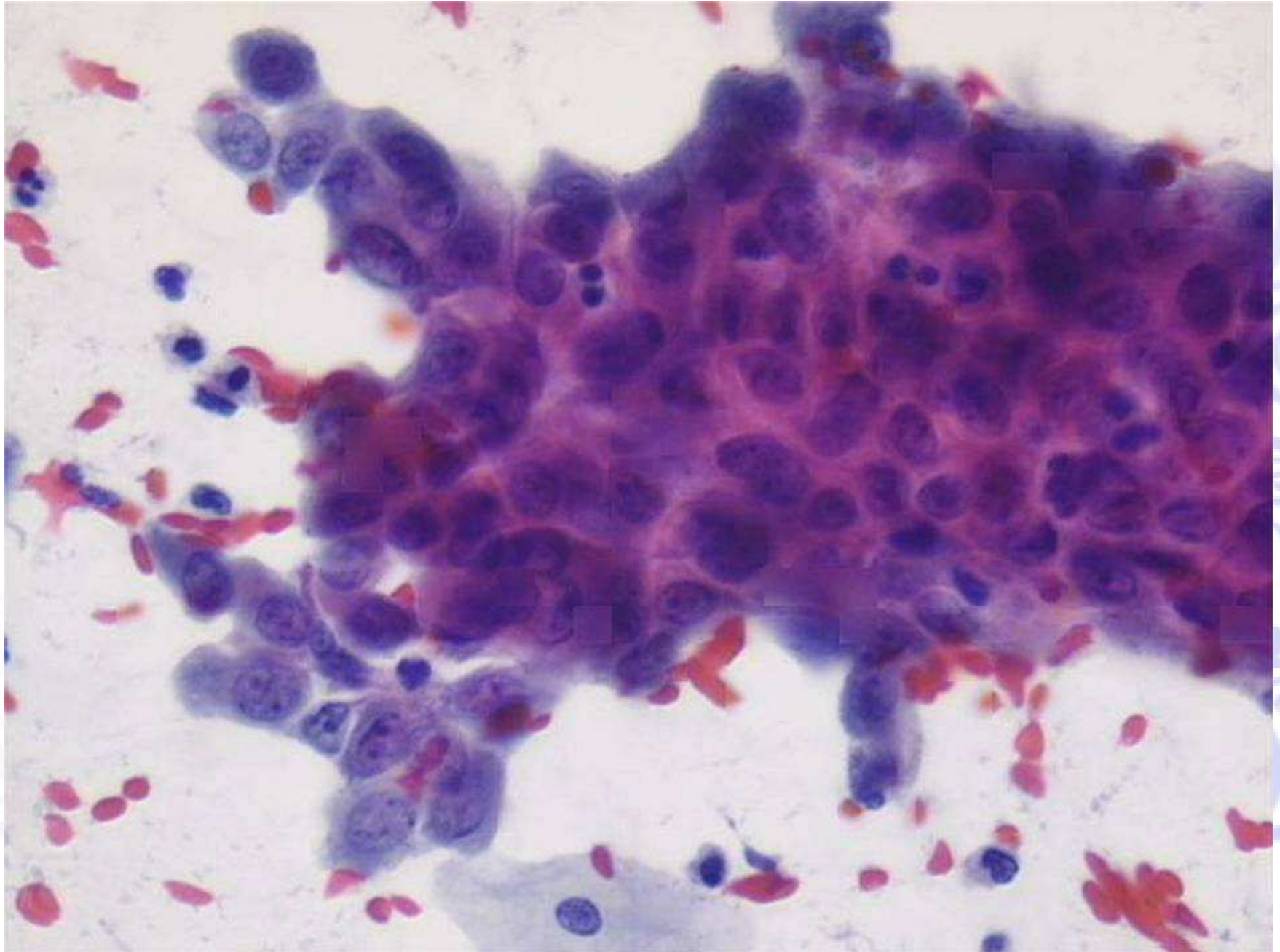
www.pearsoned.com











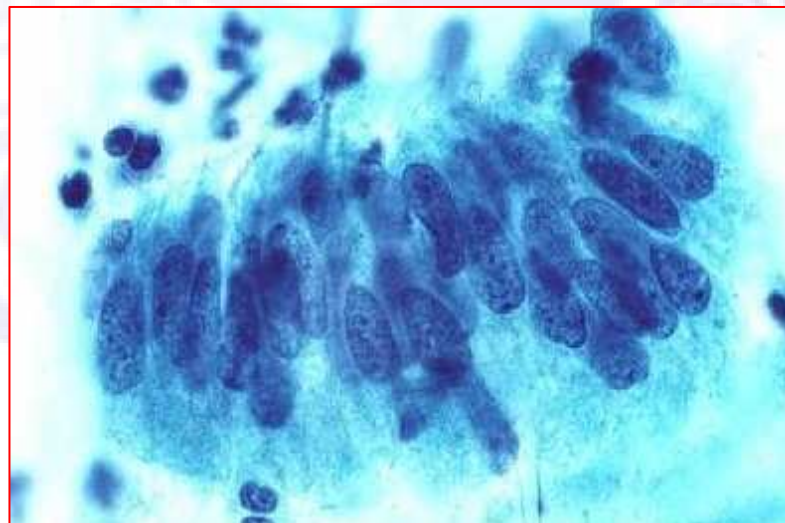
www.pearsoned.com

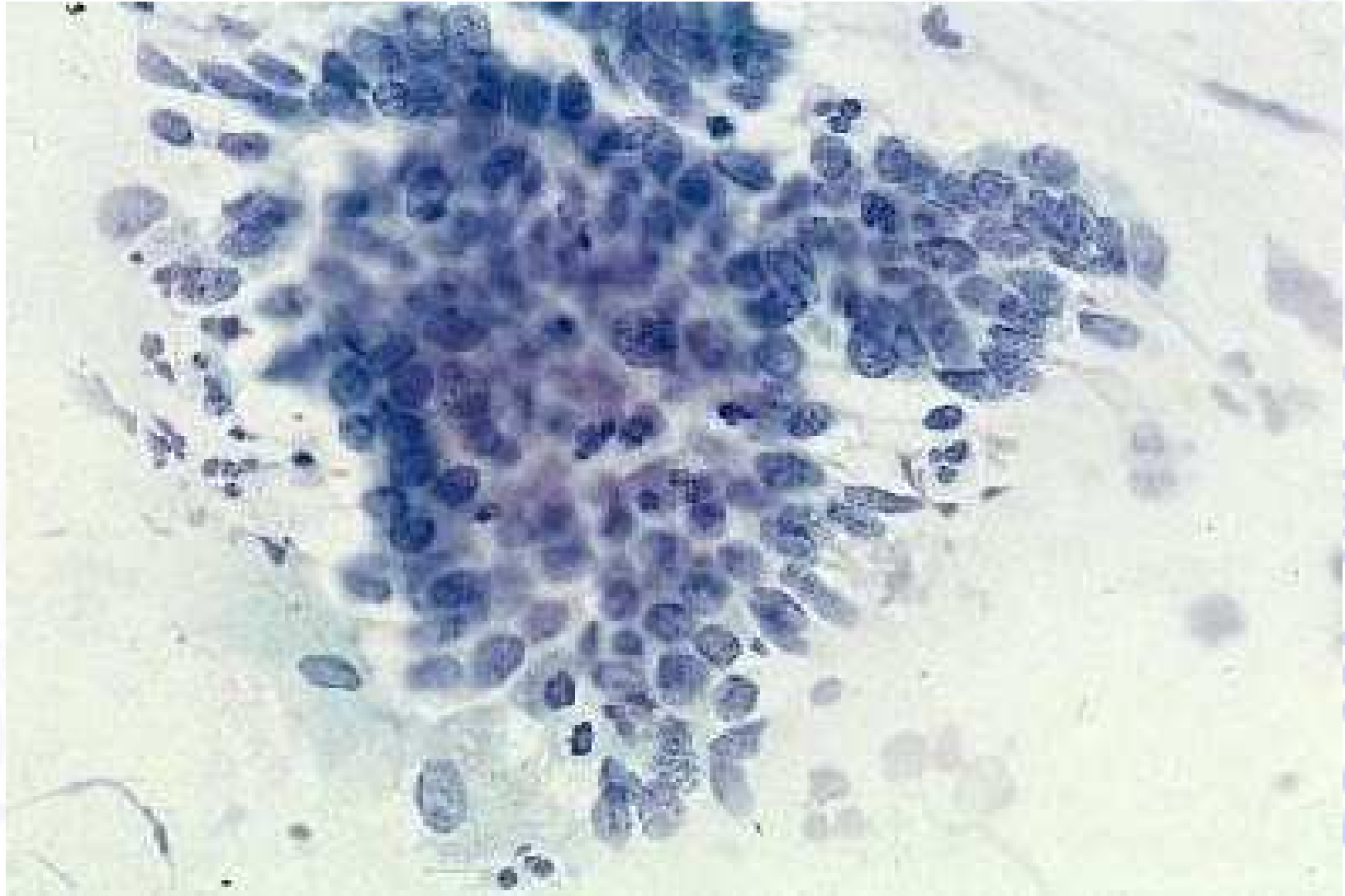
Cellule endocervicali atipiche, probabile neoplasia

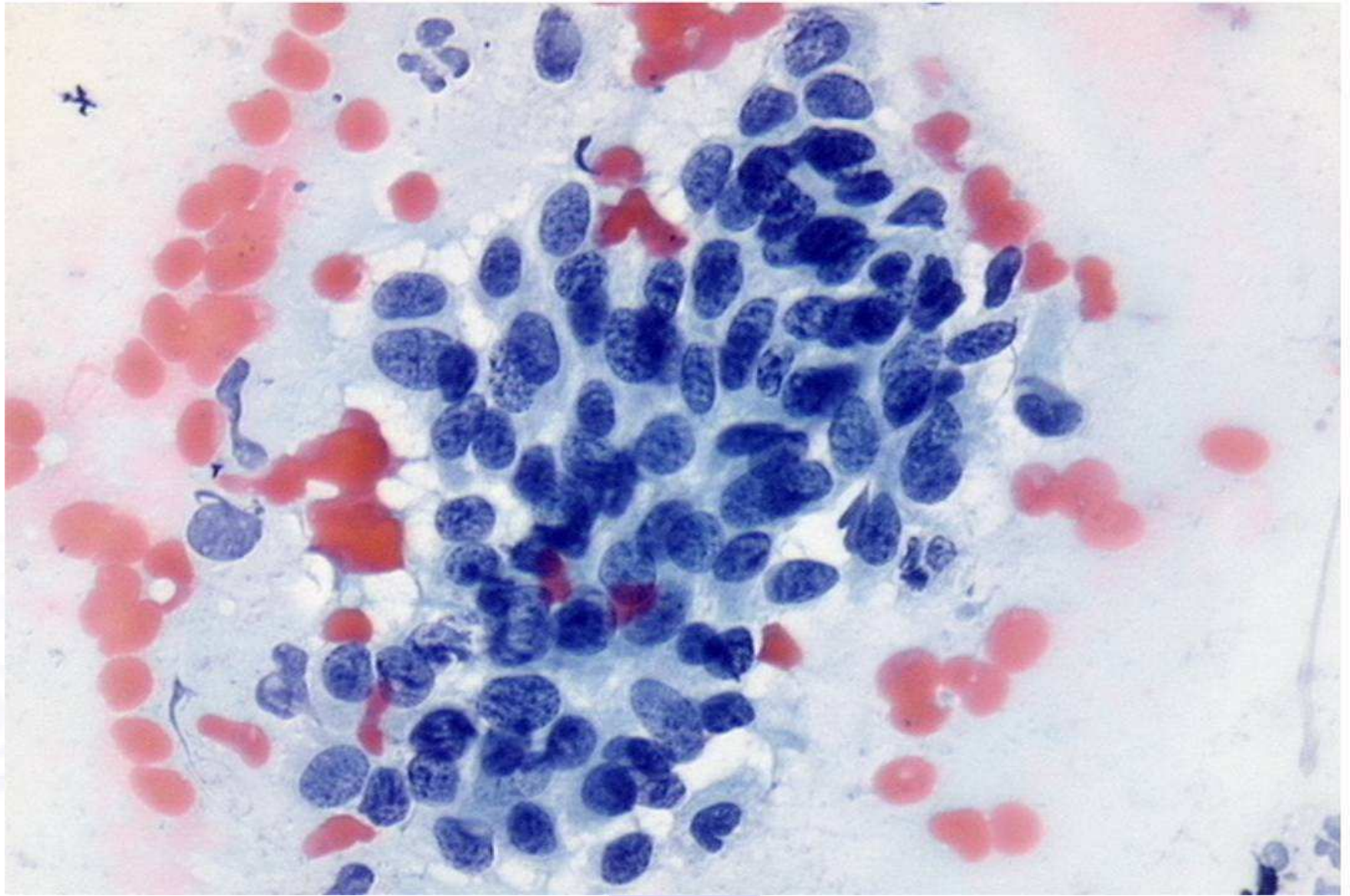
La morfologia cellulare si avvicina, sia quantitativamente che qualitativamente, all'interpretazione di adenocarcinoma in situ o di adenocarcinoma infiltrante

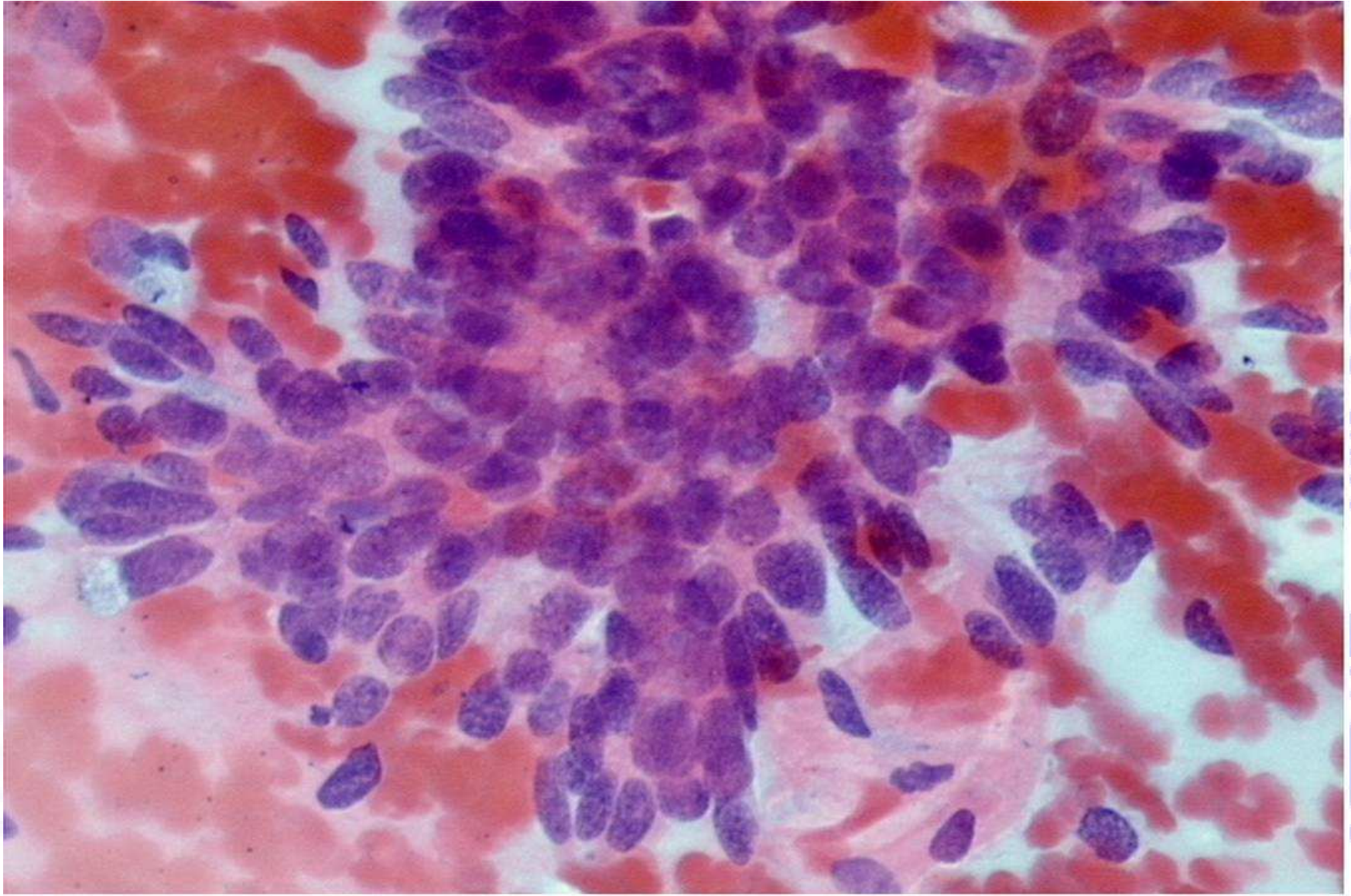
Criteri morfologici:

- Cellule anormali in lembi e a nastro con affollamento e sovrapposizione nucleare
- Nuclei ingranditi e lieve ipercromasia
- Rare mitosi
- Rapporto N/C aumentato, quantità di citoplasma ridotta e bordi cellulari mal definiti





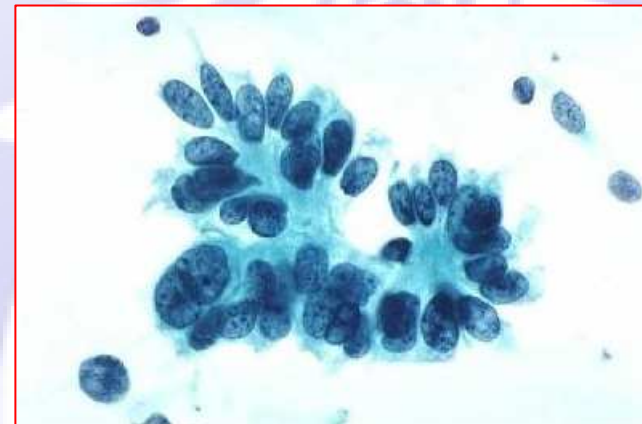


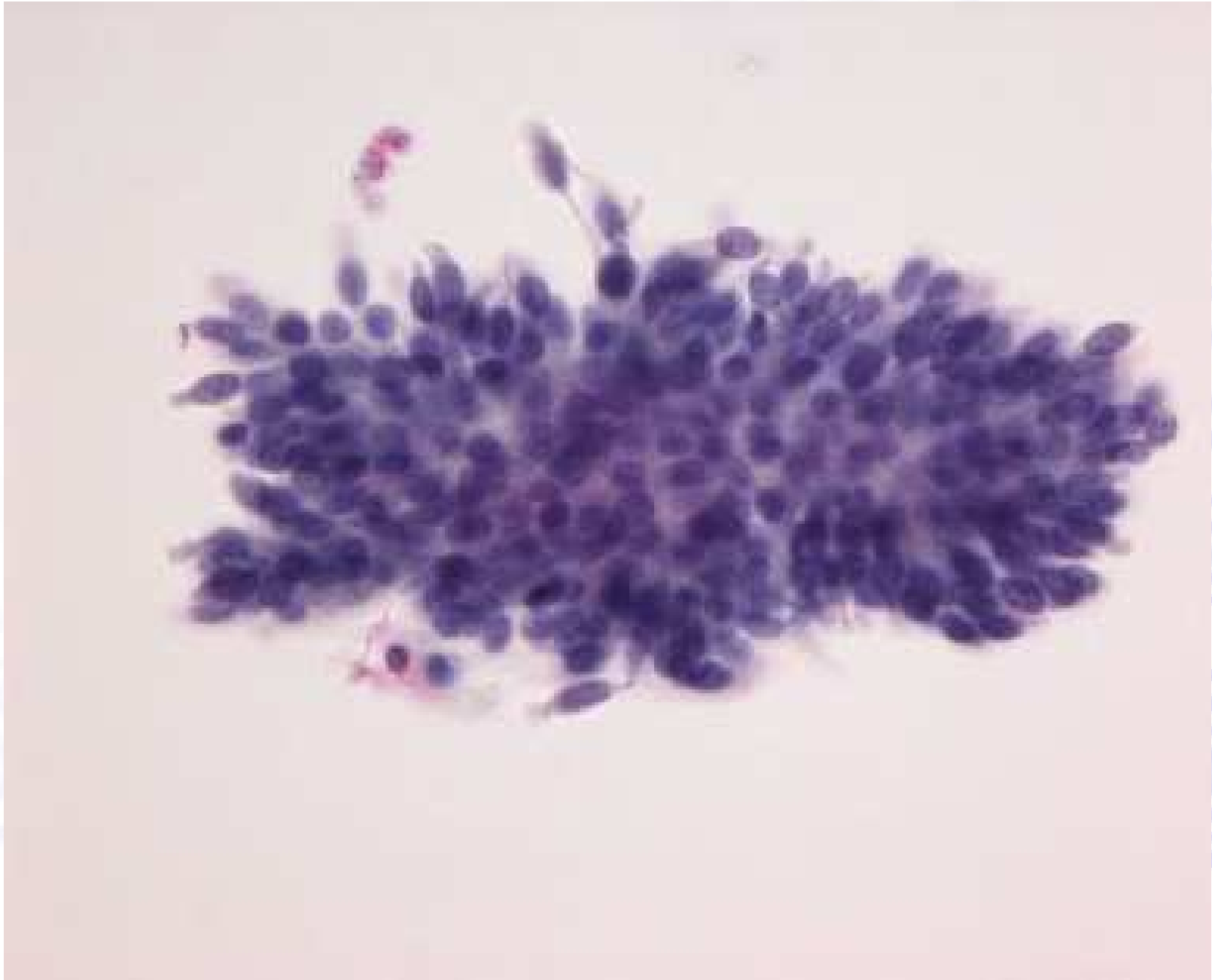


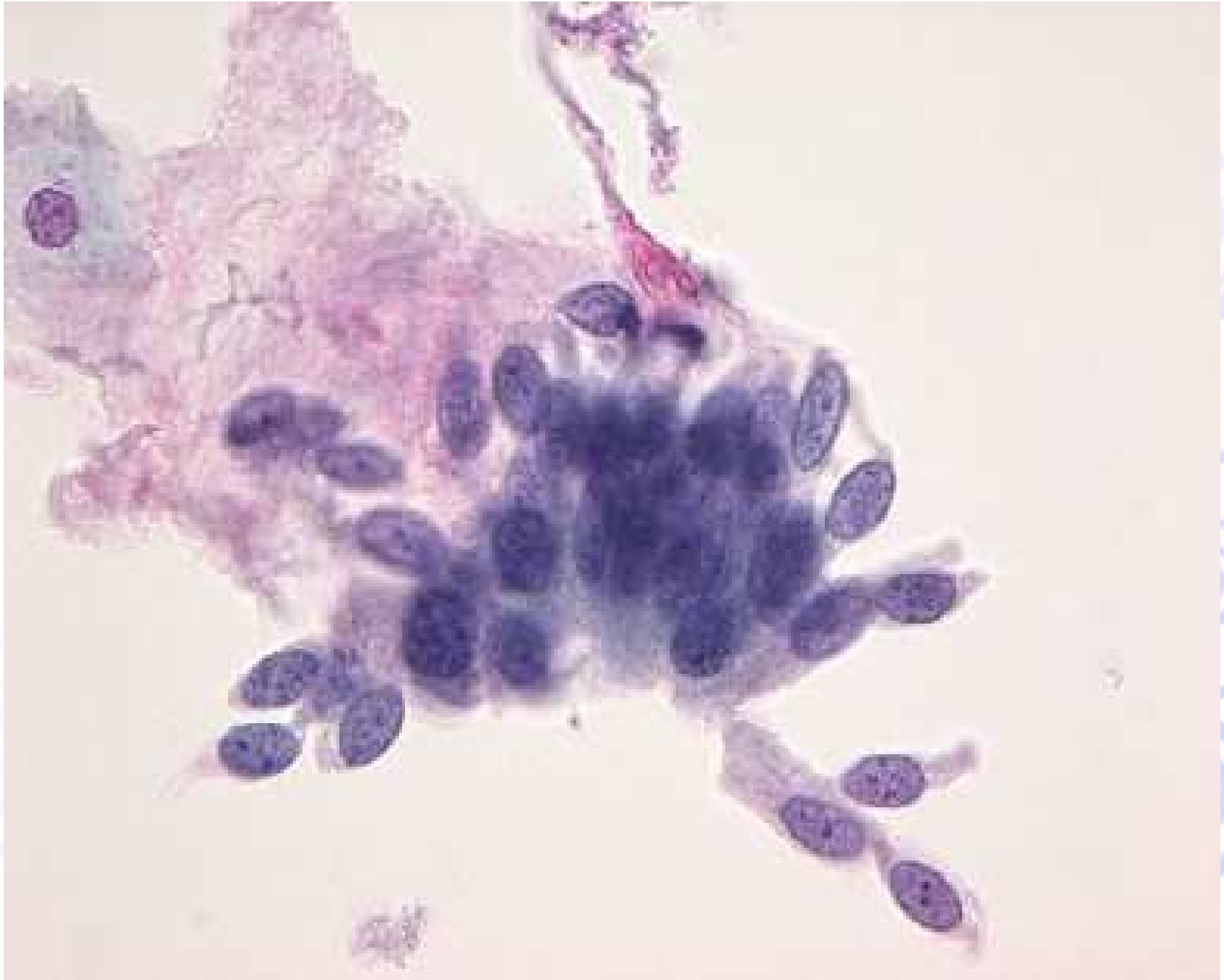
Adenocarcinoma in situ (AIS)

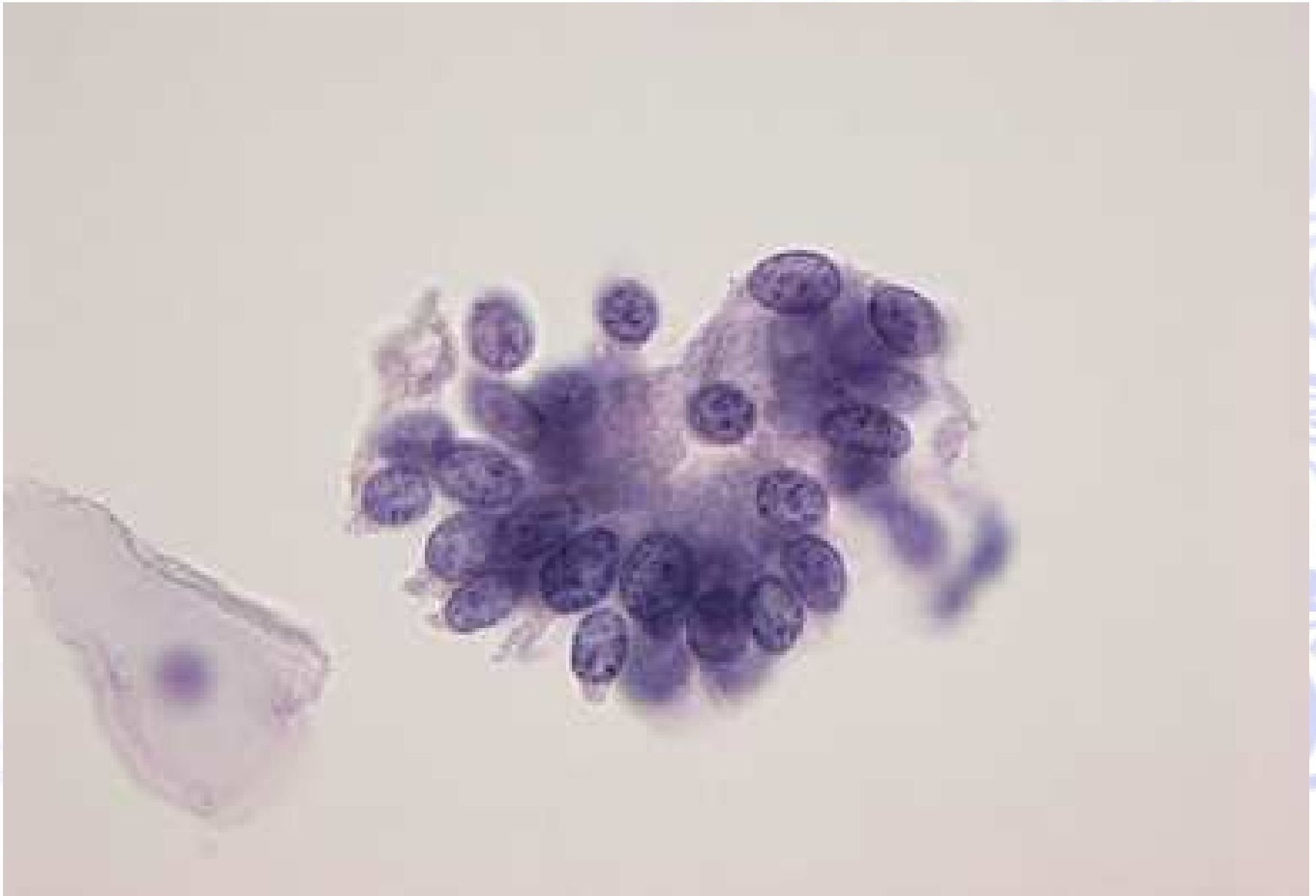Criteria morfologici:

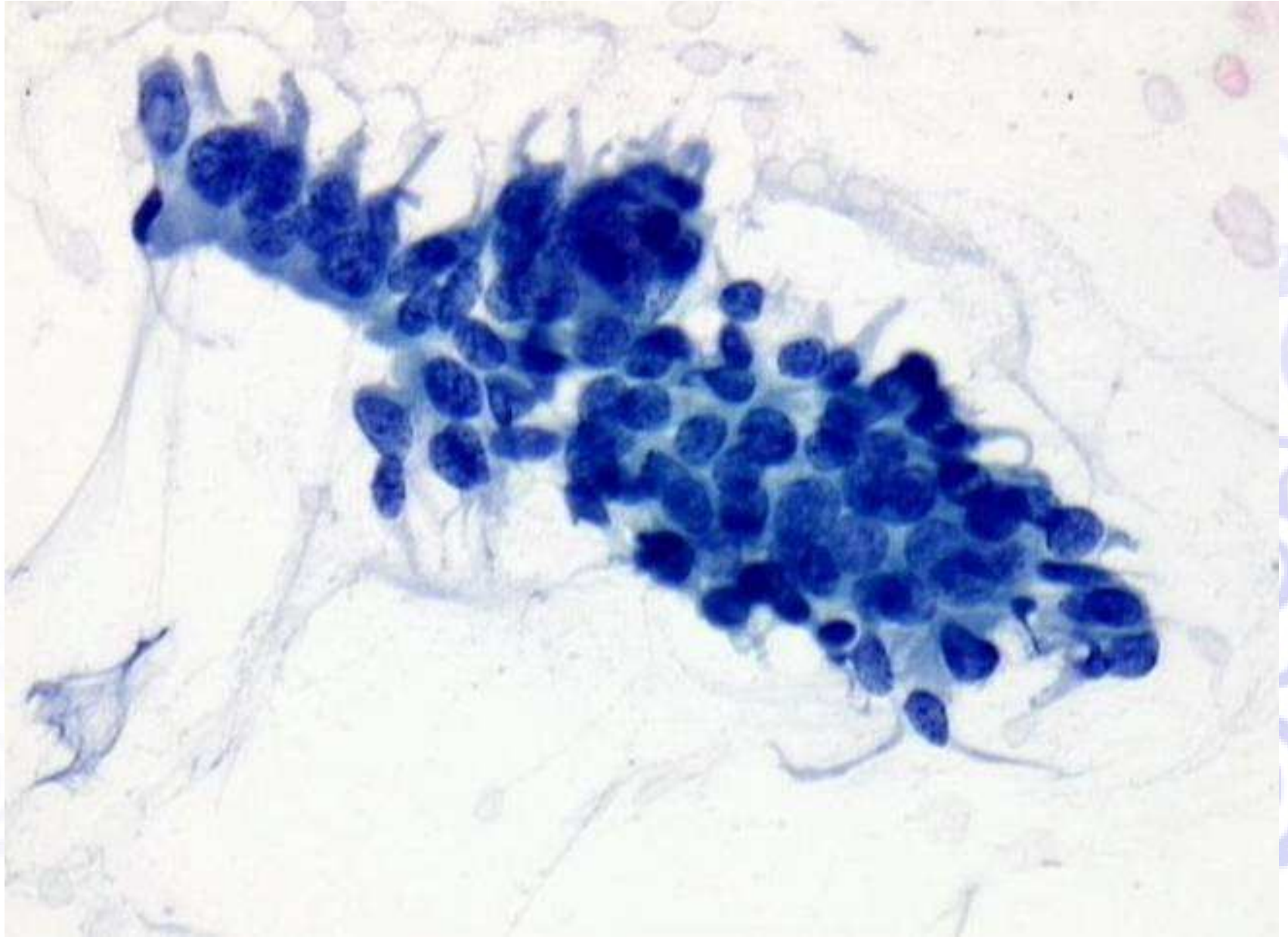
- Cellule in lembi, nastri e rosette con affollamento nucleare e sovrapposizione; alcune cellule conservano la forma colonnare
- gli aggregati cellulari hanno una disposizione dei nuclei a palizzata con nuclei e code di citoplasma protrudenti alla periferia (aspetto piumoso o feathering)
- I nuclei sono ingranditi, di dimensione variabile, di forma ovale o allungata e stratificati
- Ipercromasia nucleare, con cromatina diffusamente dispersa, grossolanamente granulare
- Nucleoli piccoli o incospicui
- Mitosi e corpi apoptotici comuni
- Fondo pulito (assenza di diatesi tumorale)

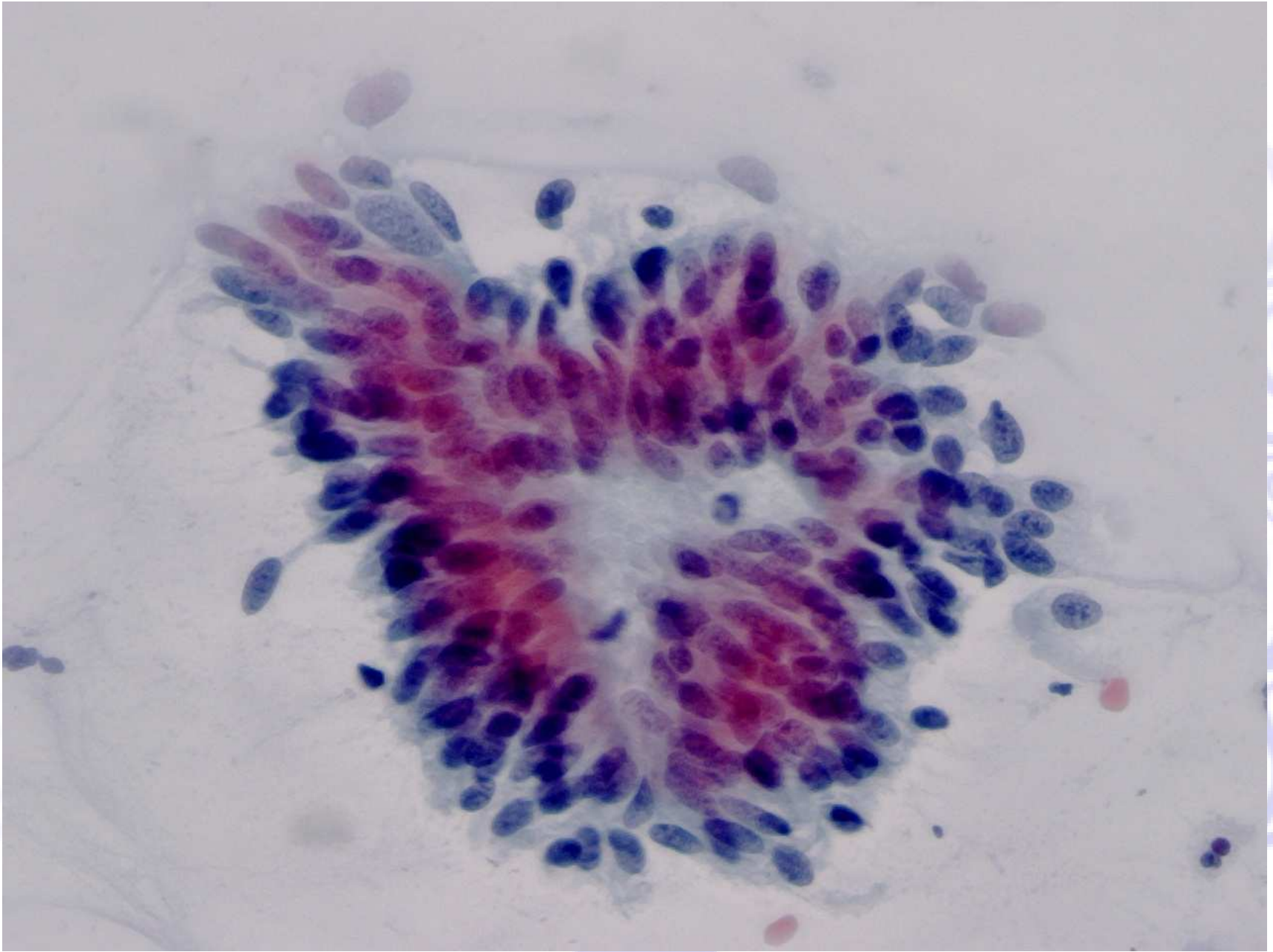


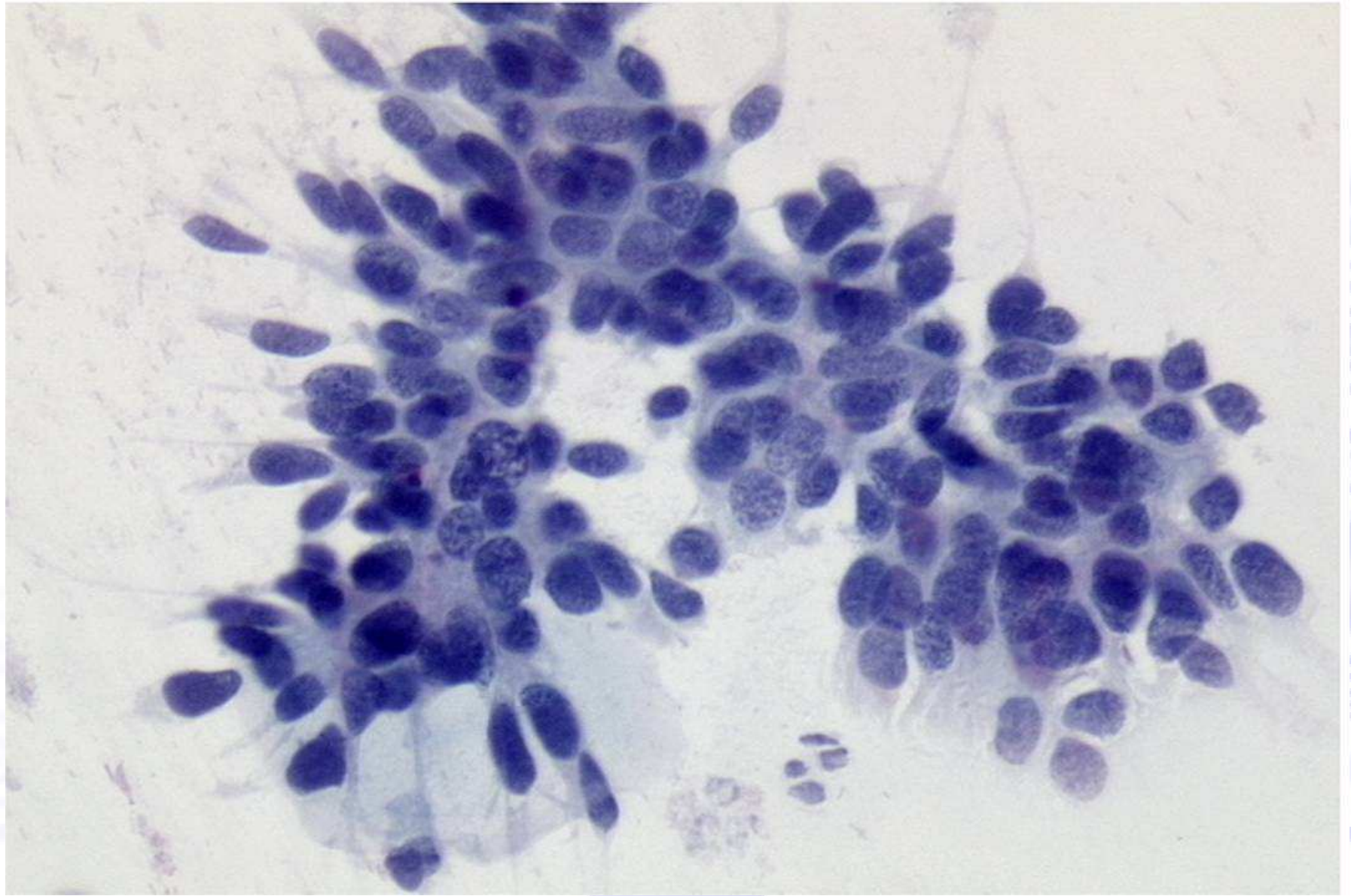


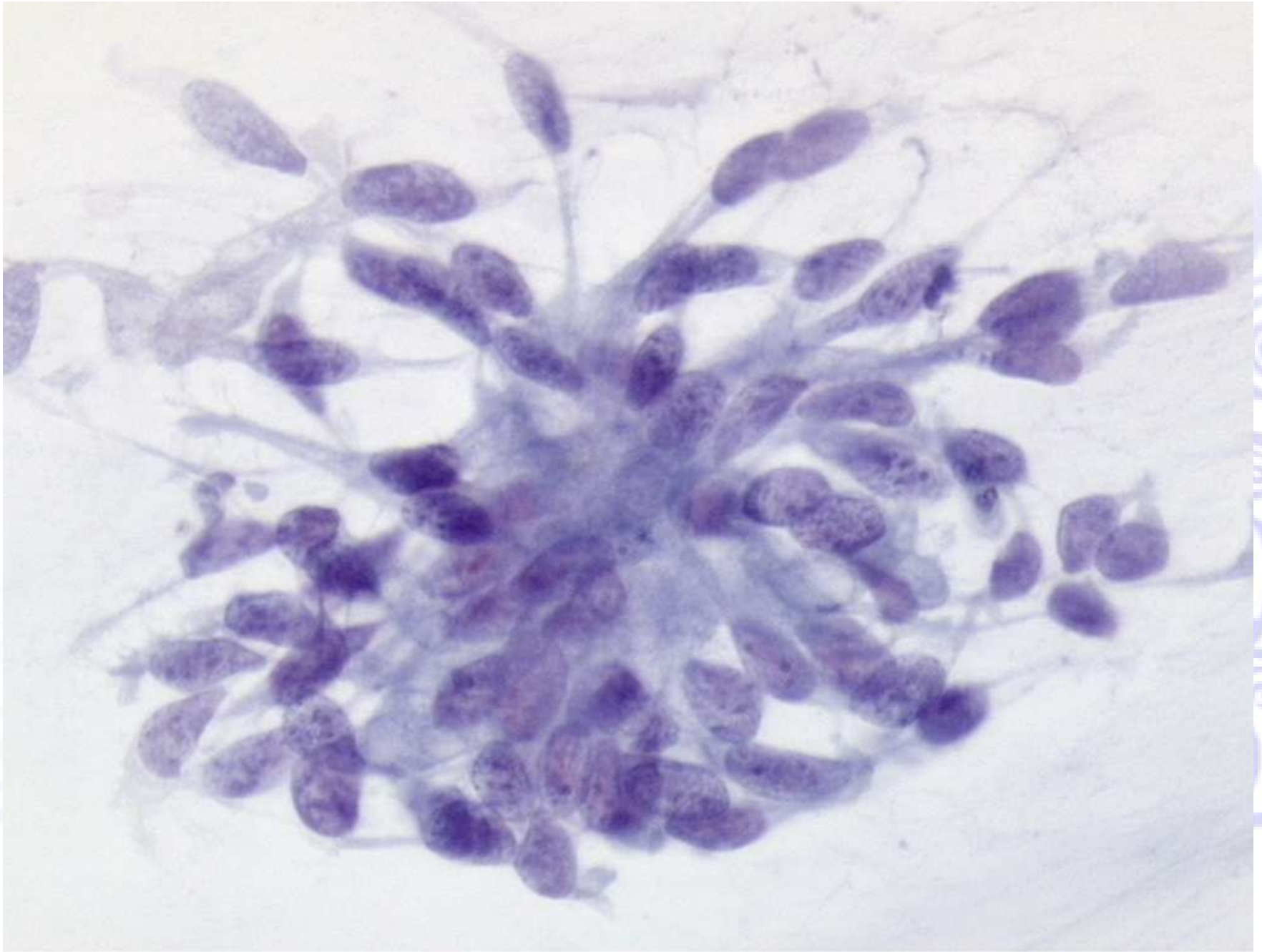












Microscopic image of a plant tissue section, showing numerous elongated, dark purple structures (likely xylem vessels or tracheids) arranged in a radial pattern, surrounded by lighter-colored cortical cells.

Adenocarcinoma endocervicale

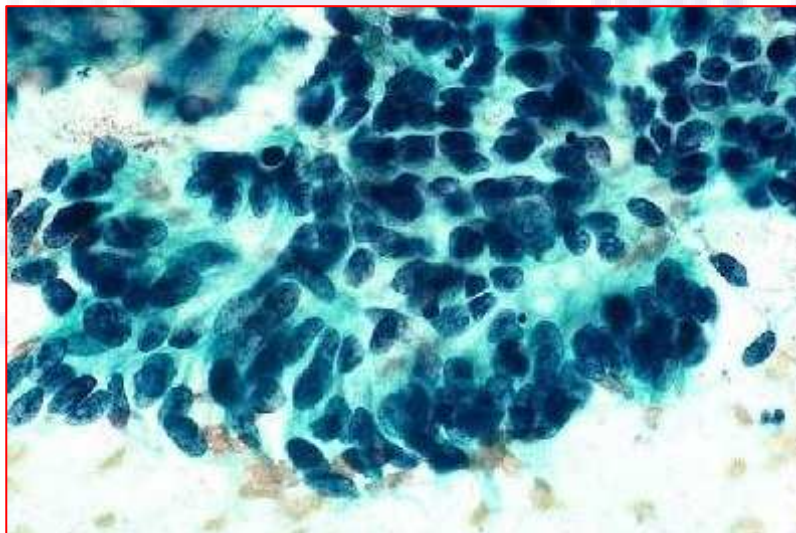
I criteri citologici si sovrappongono a quelli già descritti per AIS, ma possono essere presenti i caratteri dell'infiltrazione.

TBS 2001

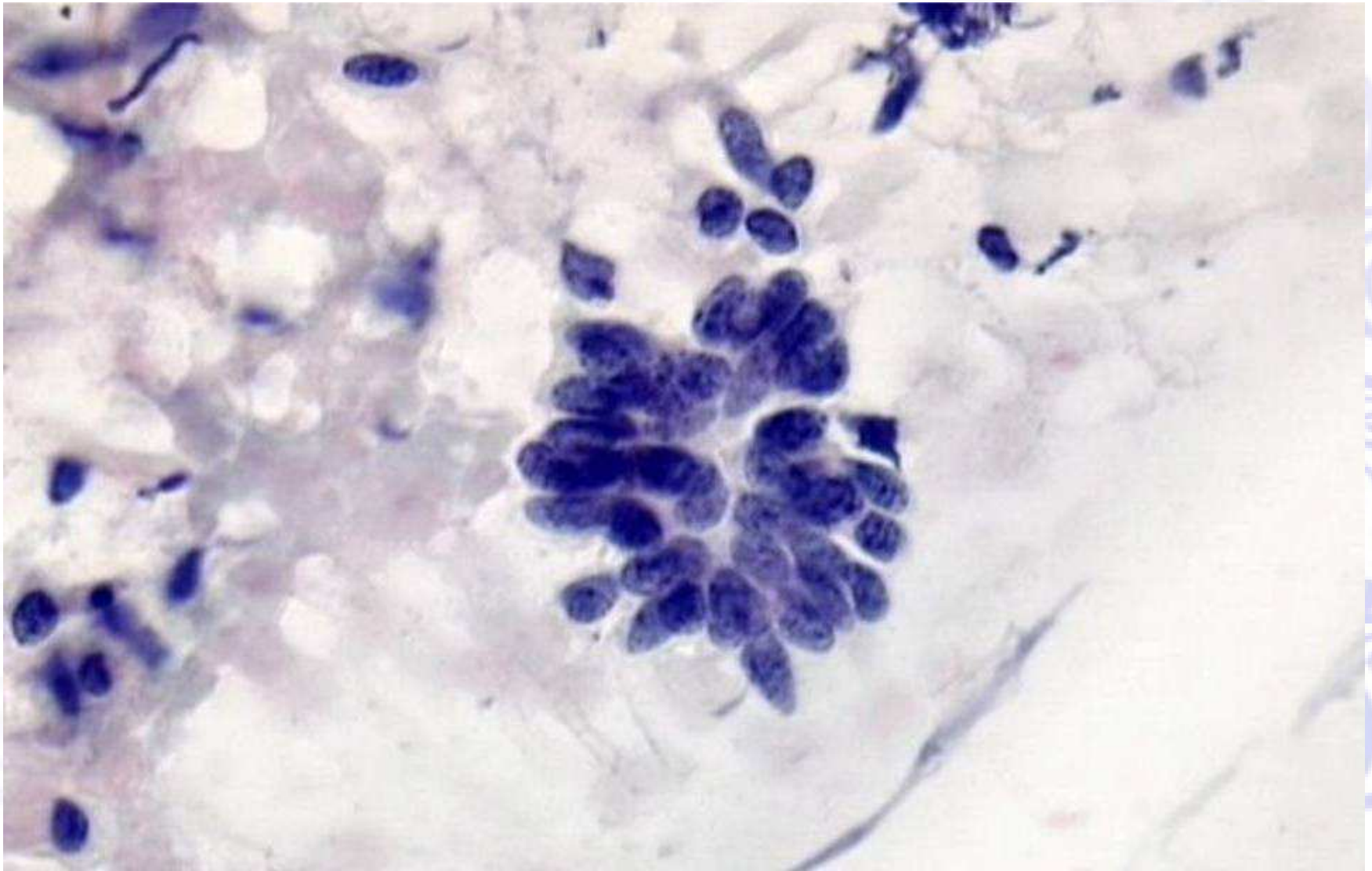
Adenocarcinoma endocervicale

Criteria morfologici:

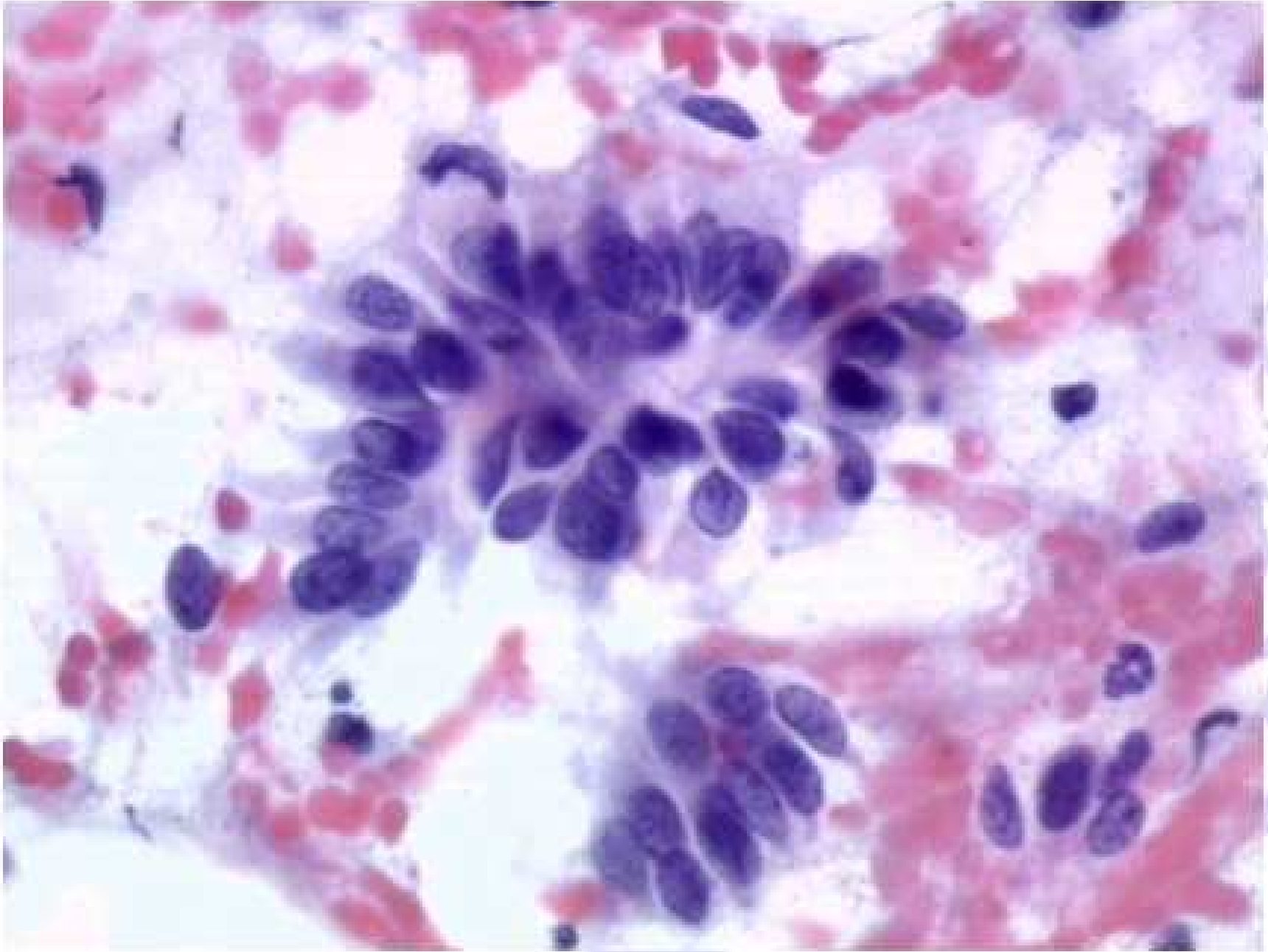
- Cellule singole, lembi bidimensionali o aggregati tridimensionali o sinciziali
- Nuclei ingranditi, pleomorfi con cromatina distribuita in modo irregolare, aree chiare paracromatiniche ed irregolarità della membrana nucleare
- Possono essere presenti macronucleoli
- Talvolta è presente diatesi tumorale (necrosi)

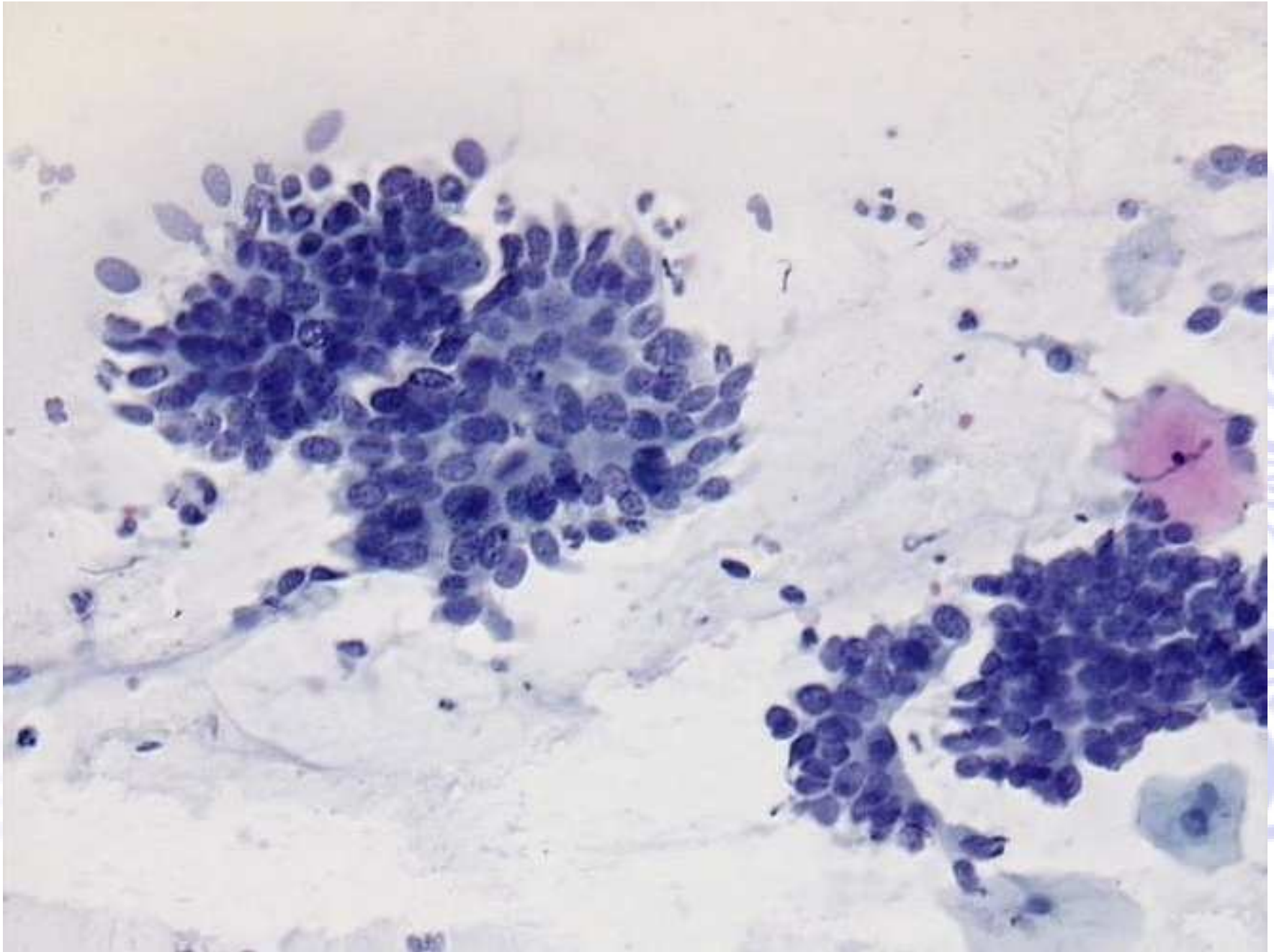


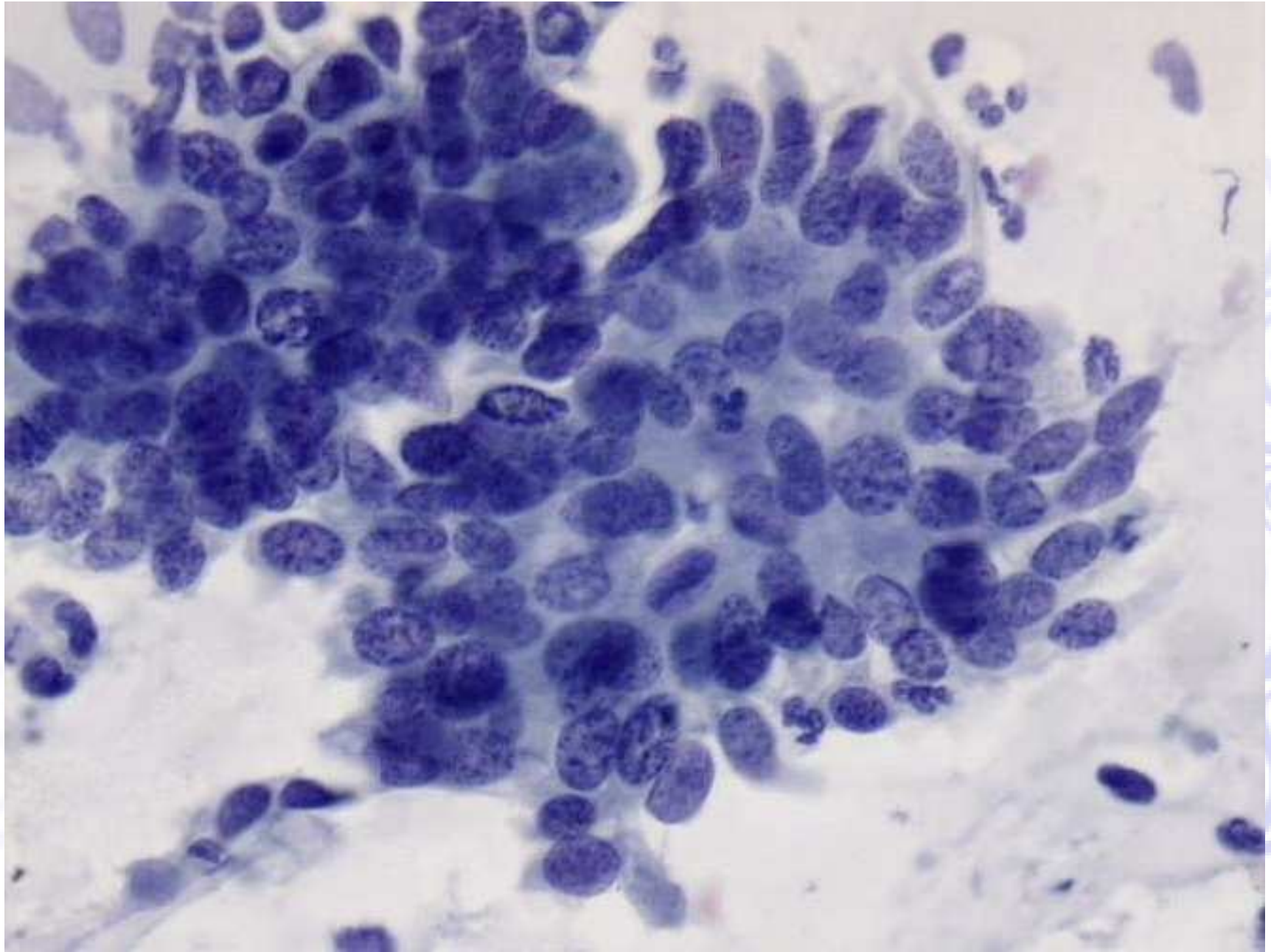
TBS 2001

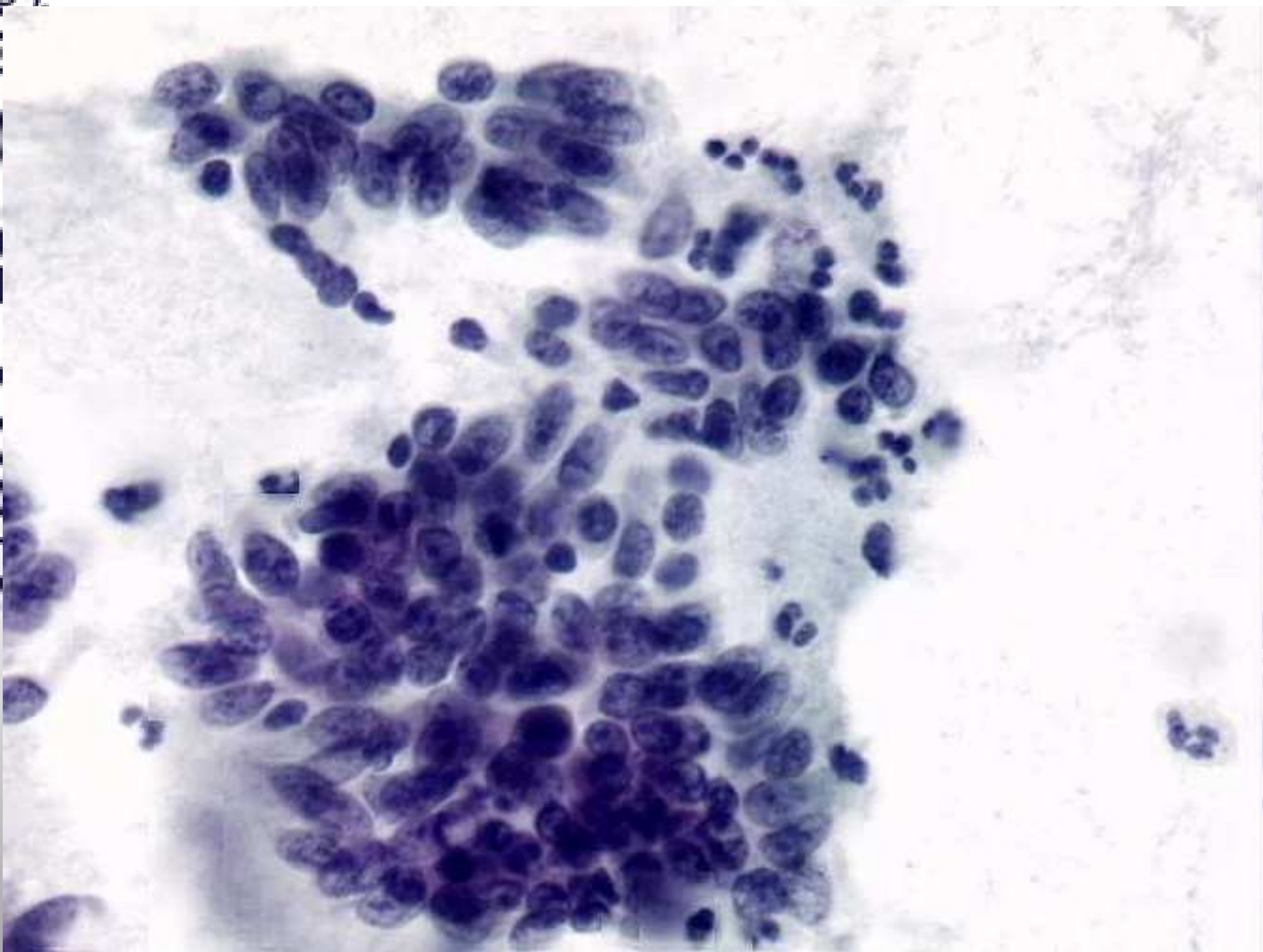


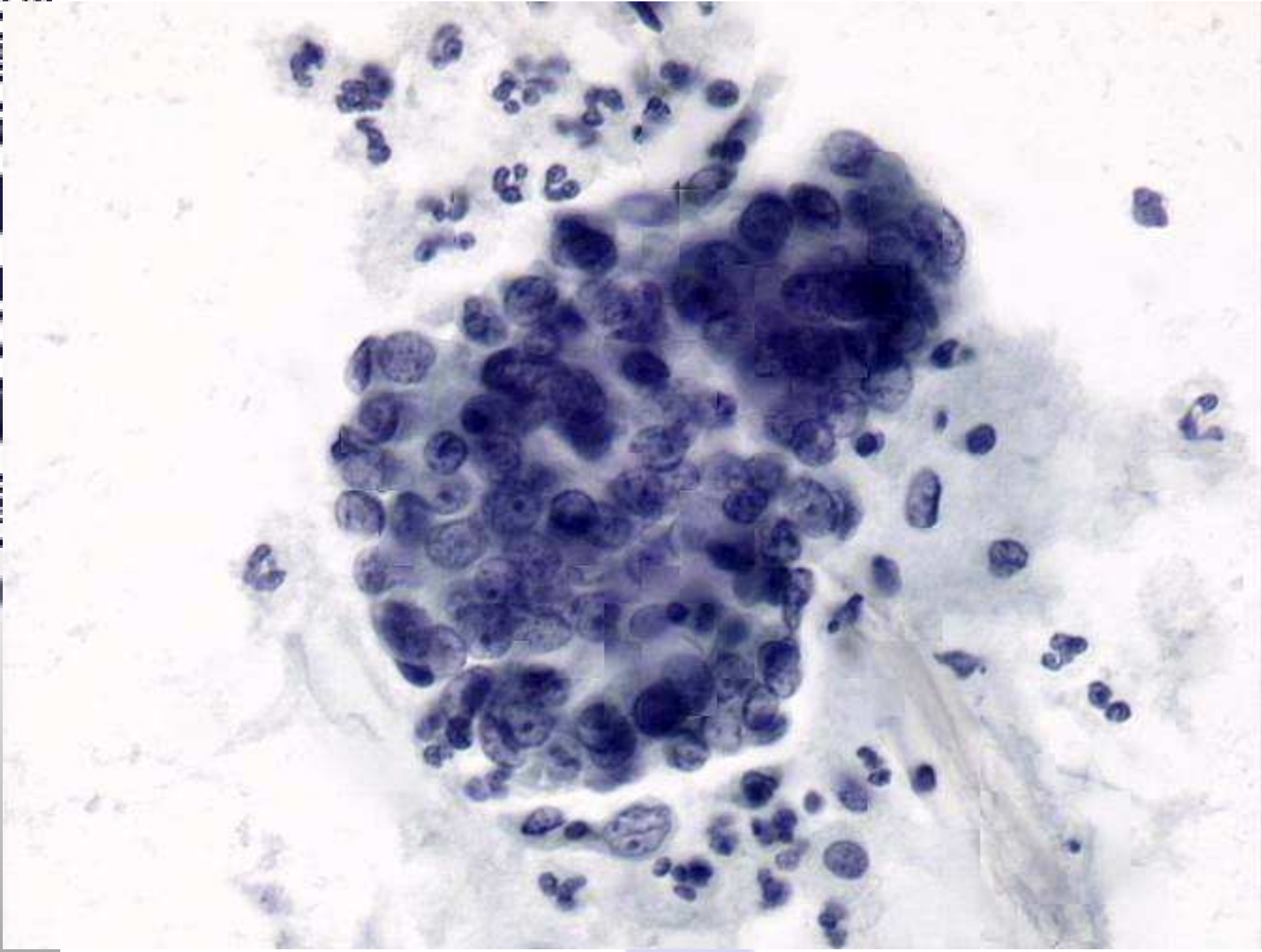
100

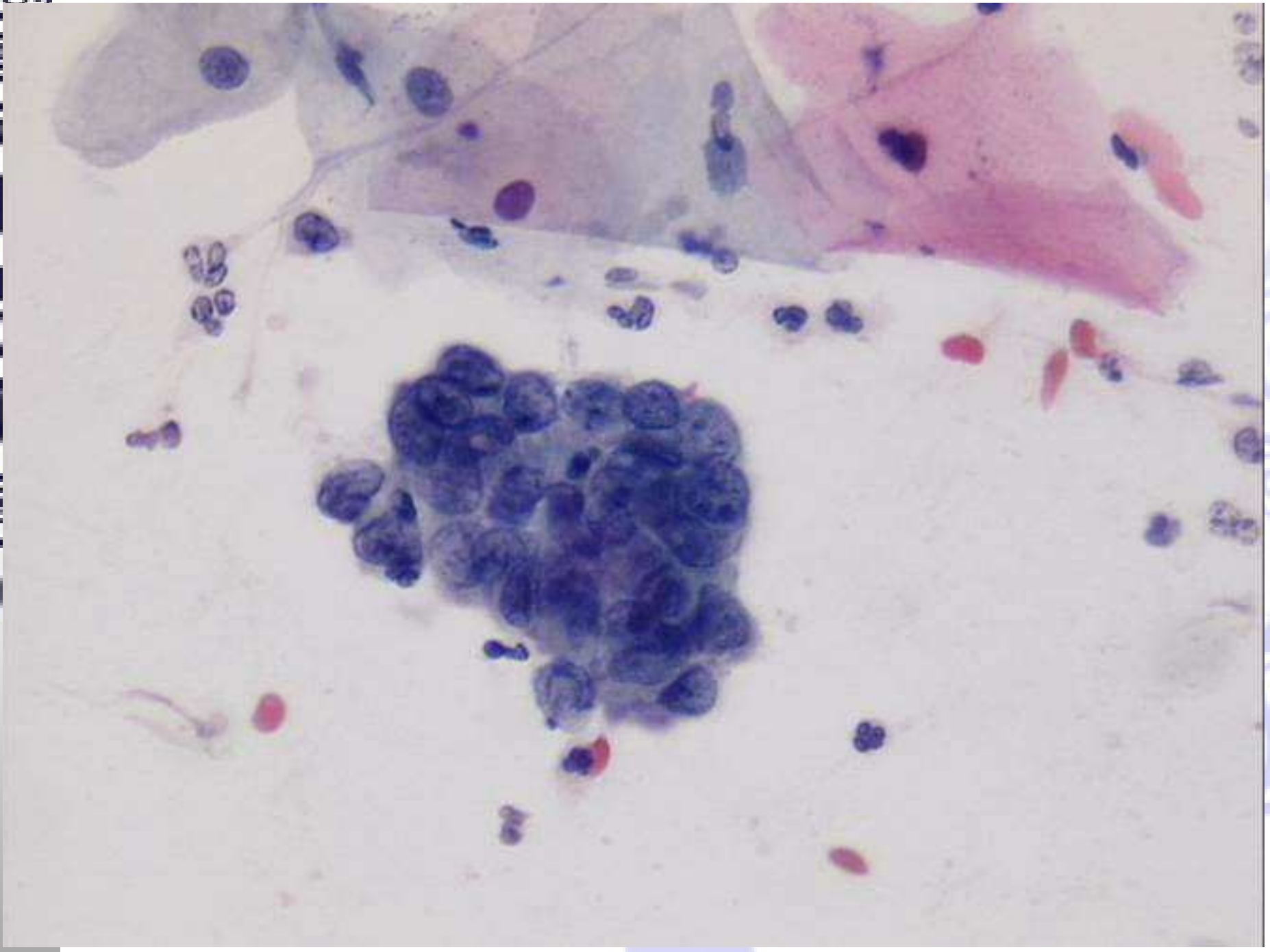


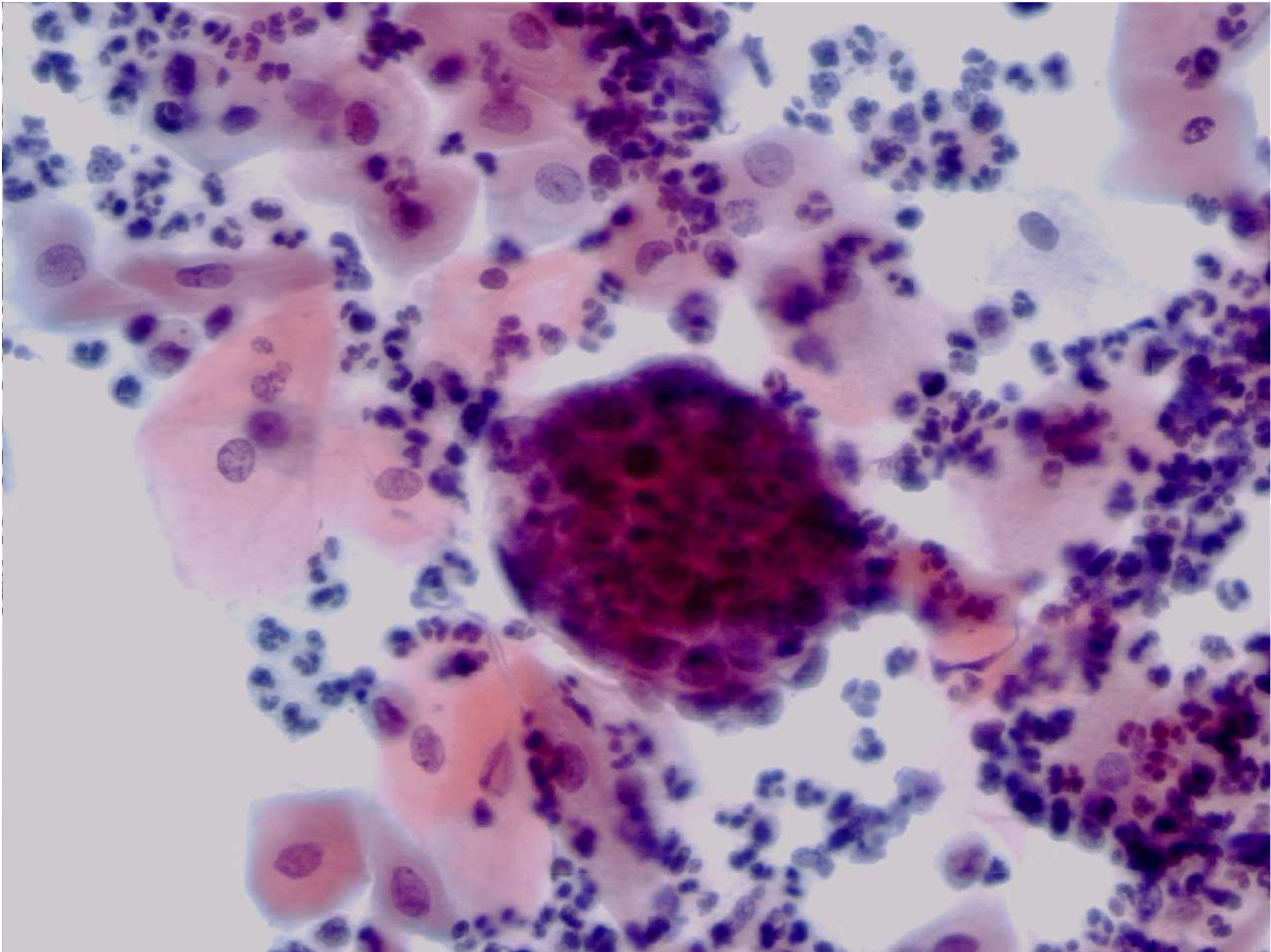


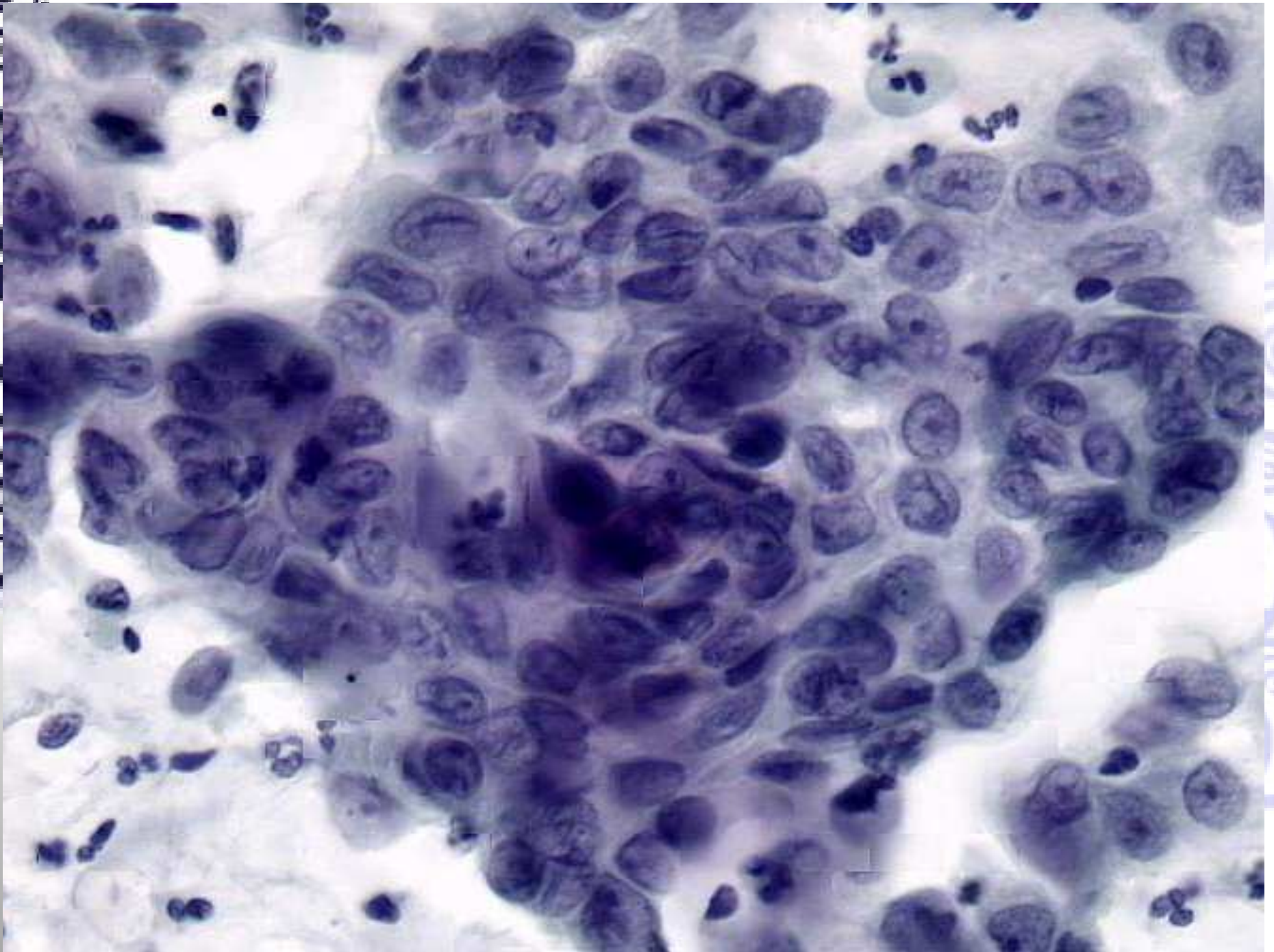



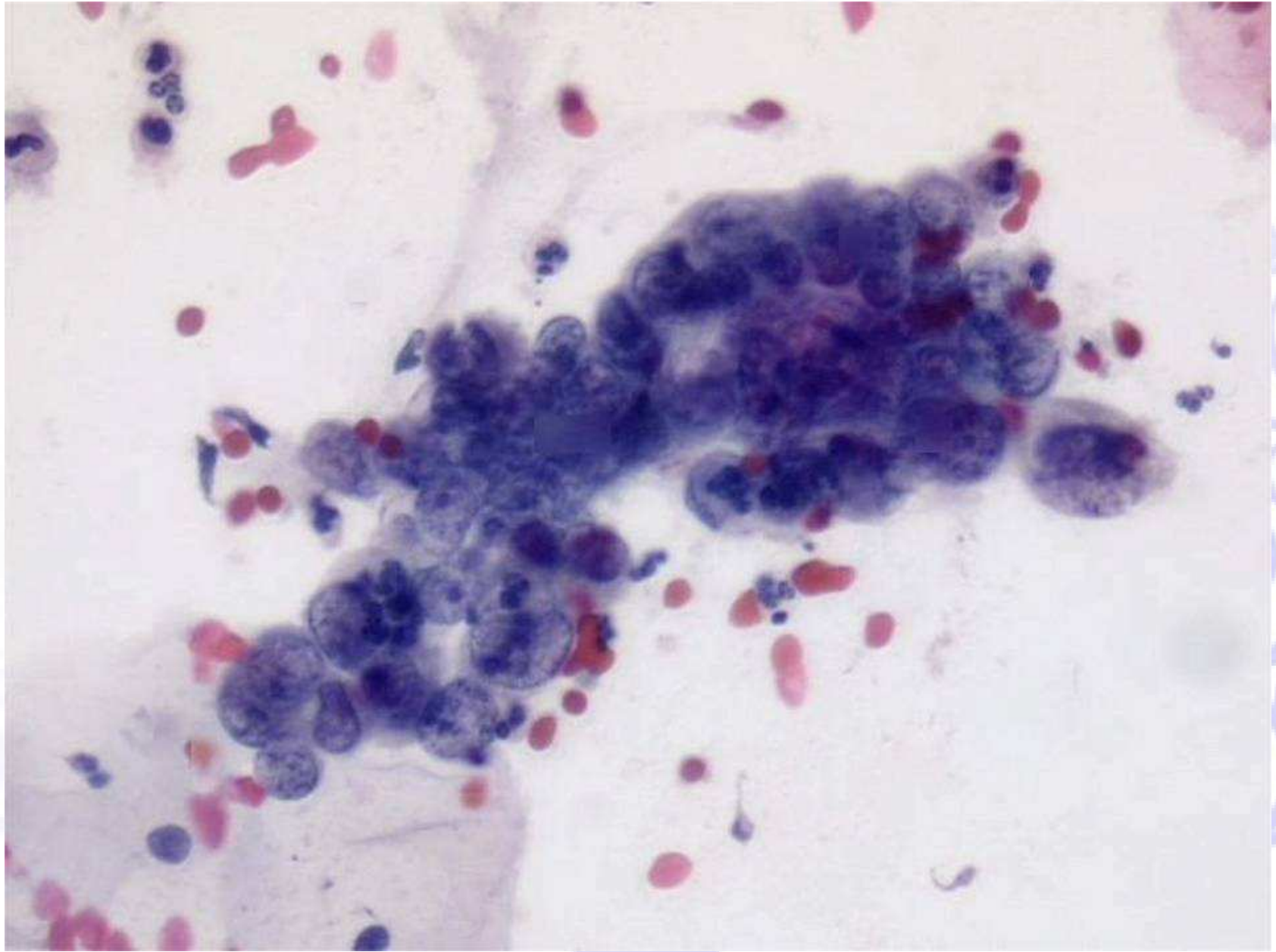


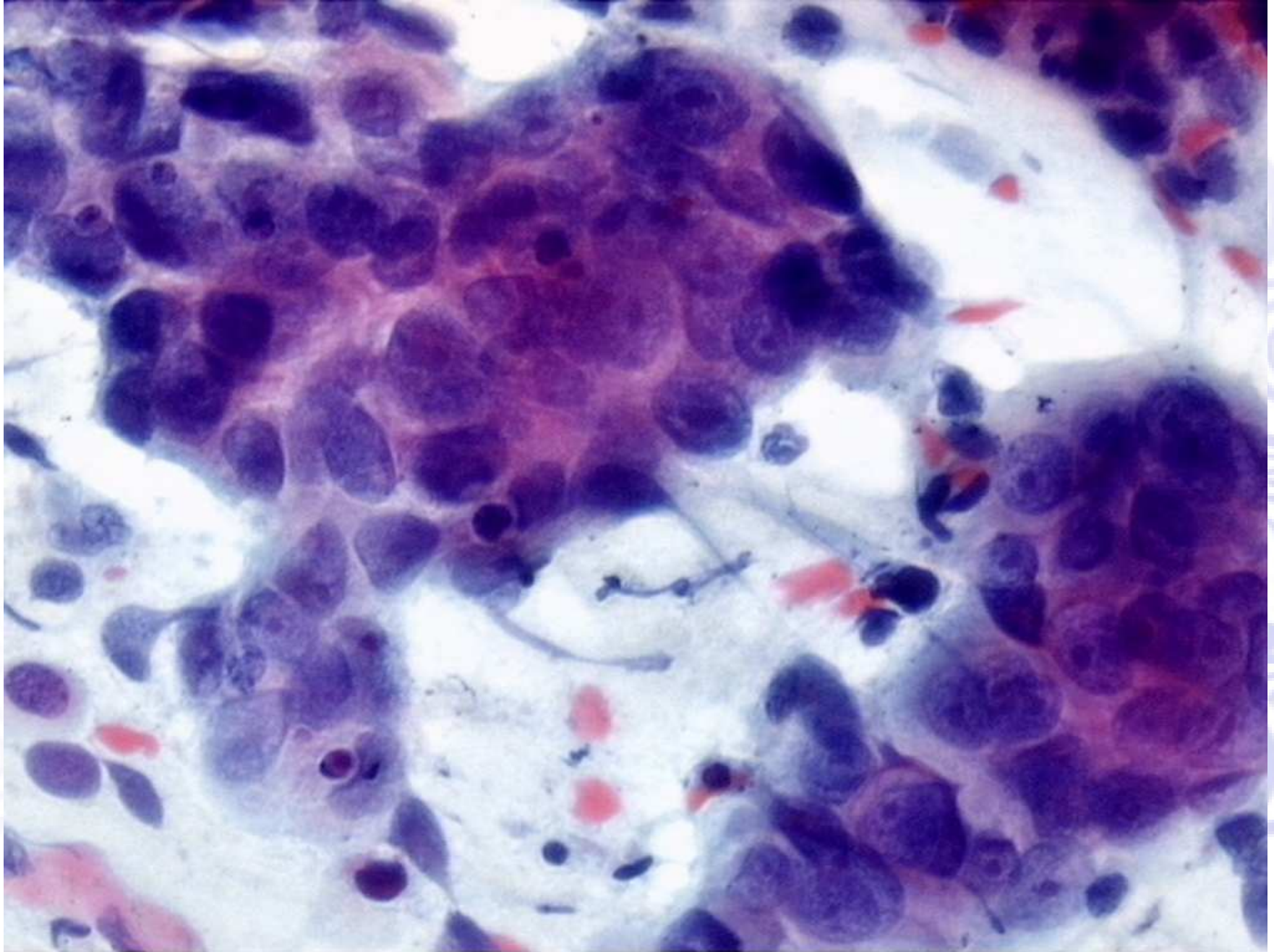






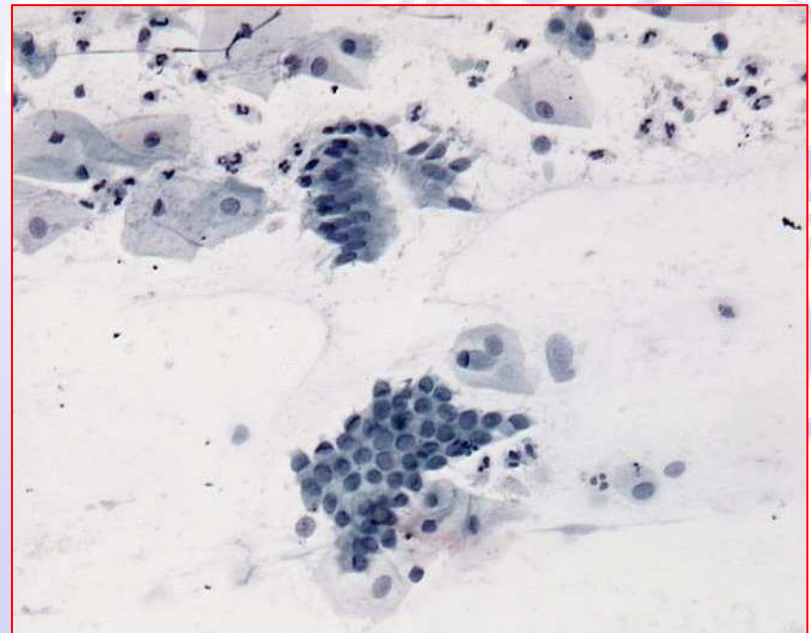
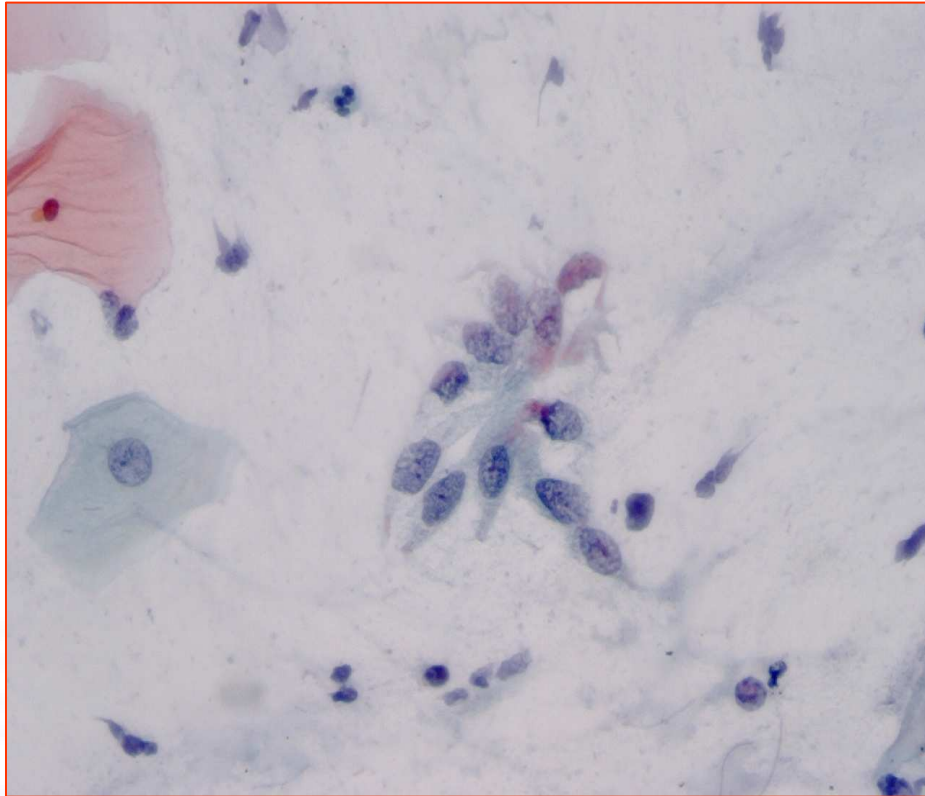




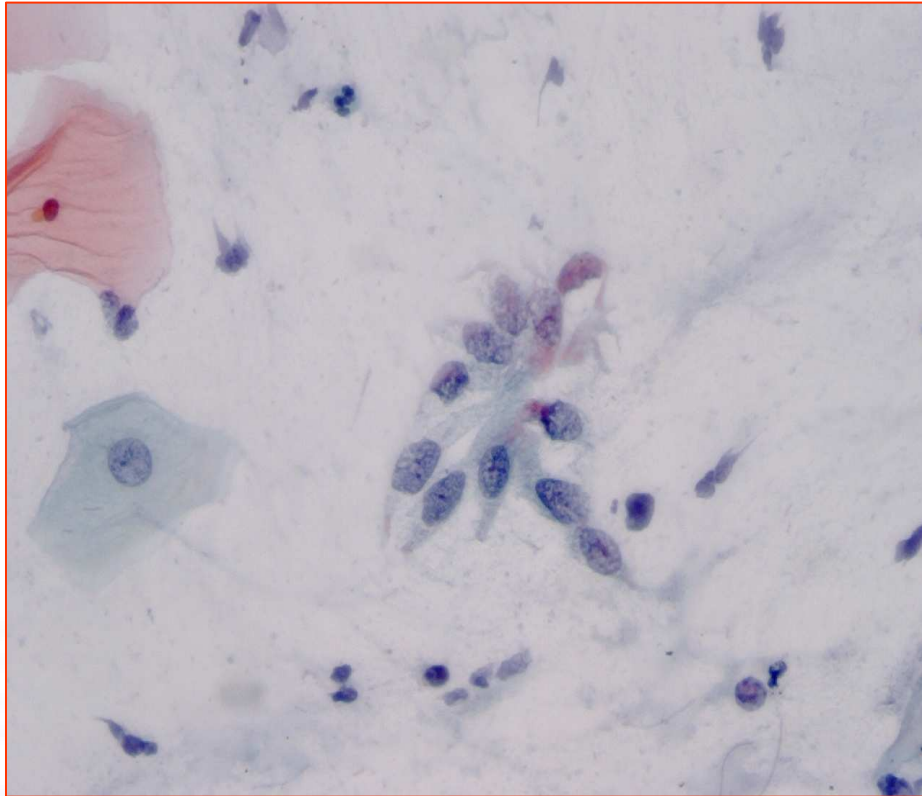


© 2010 Pearson Education, Inc. All rights reserved. This material is protected by copyright and may be reproduced in whole or in part for educational use only. For more information, contact Pearson Education, Inc., 501 Boylston Street, Boston, MA 02116.

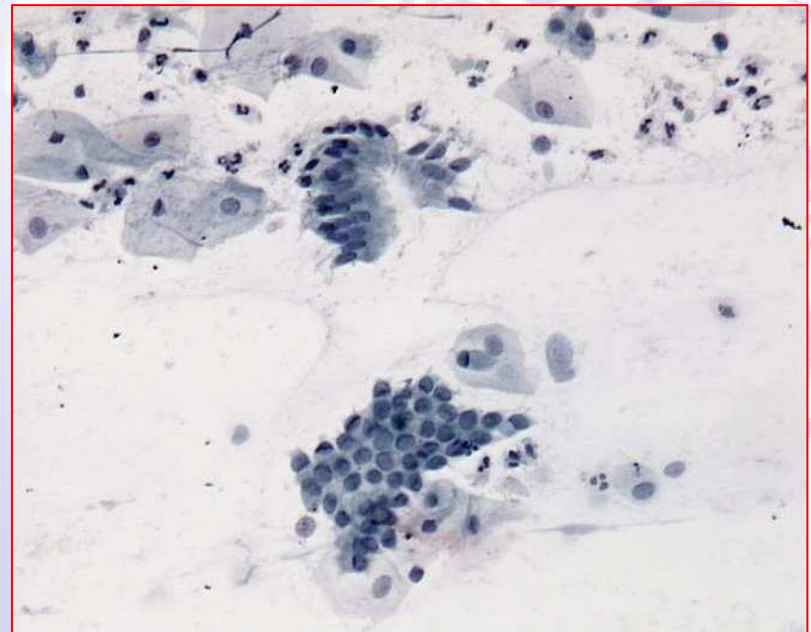
Quiz



Quiz



AIS



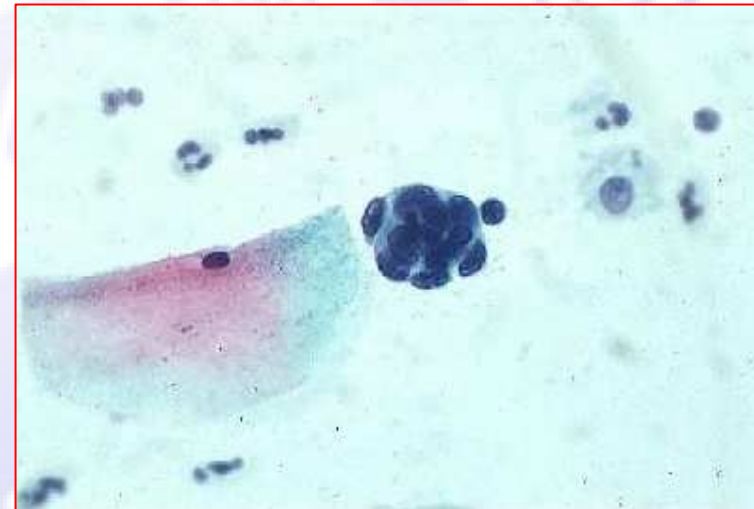Cellule endocervicali

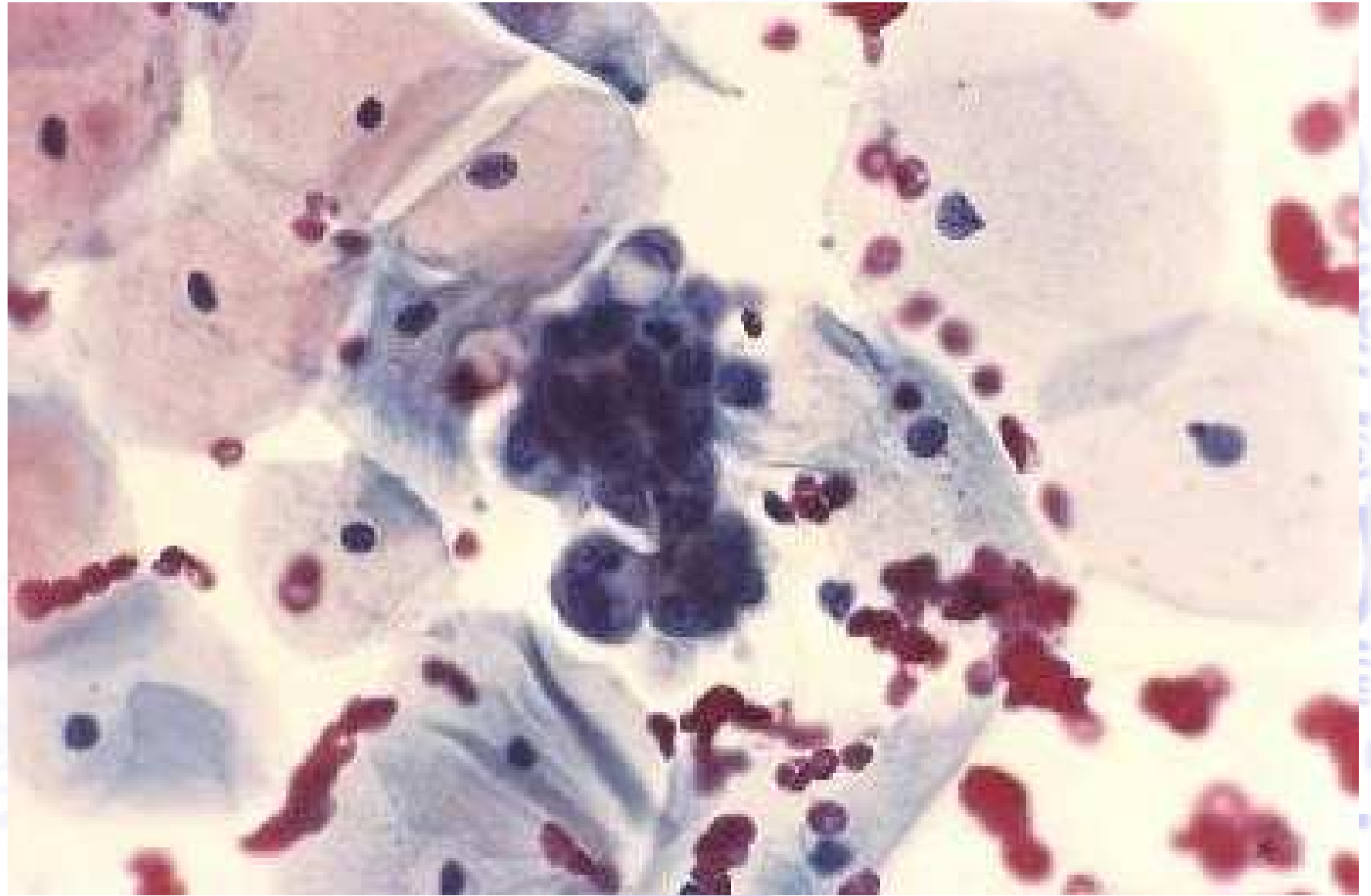
Cellule endometriali atipiche

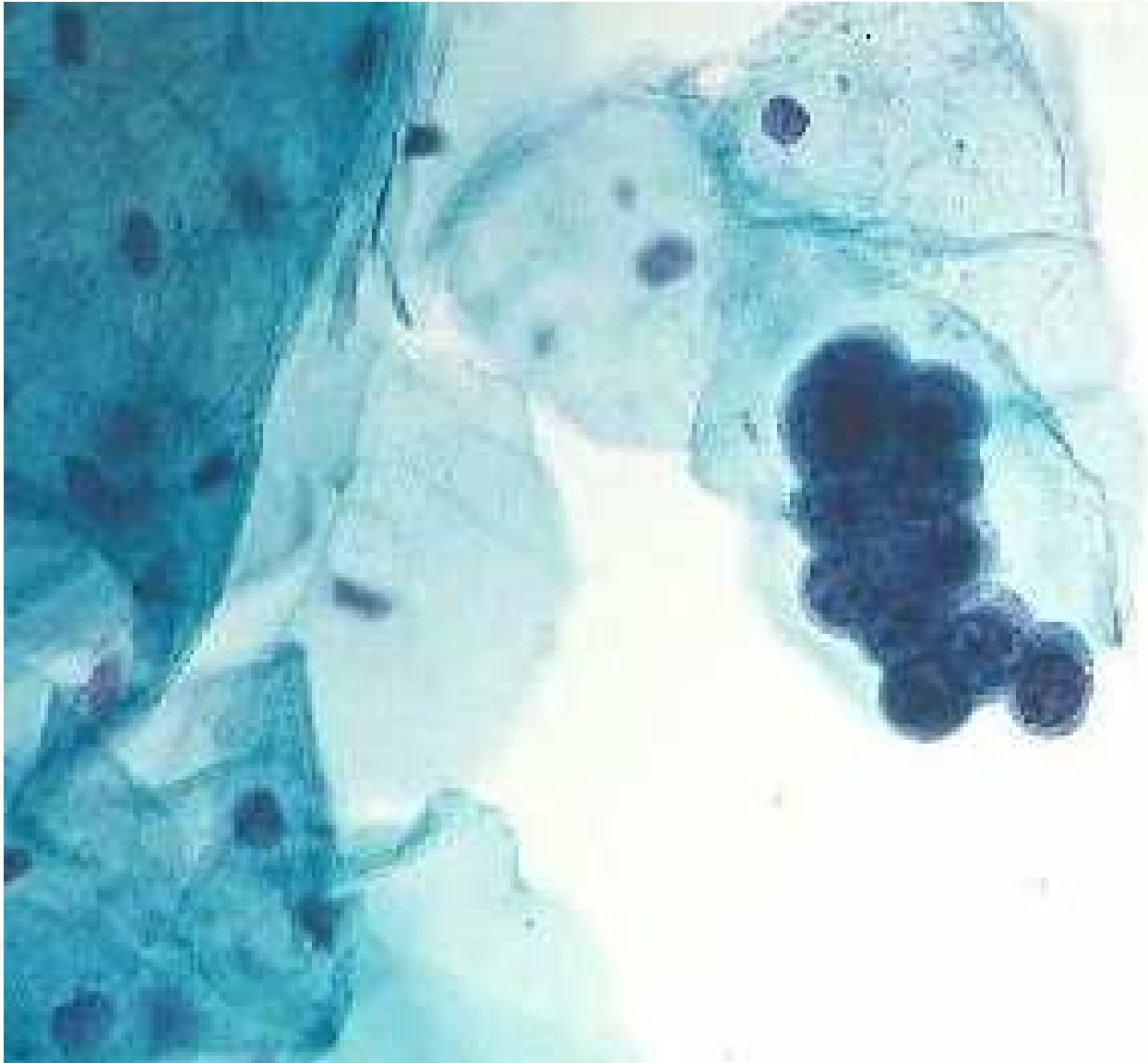
Criteri morfologici:

- Cellule in piccoli gruppi solitamente 5/10 cellule per gruppo
- Citoplasma scarso, talora vacuolato
- Bordi cellulari mal definiti
- Nuclei lievemente ingranditi
- Lieve ipercromasia
- Possono essere presenti piccoli nucleoli
- Mitosi rare

(TBS 2001)







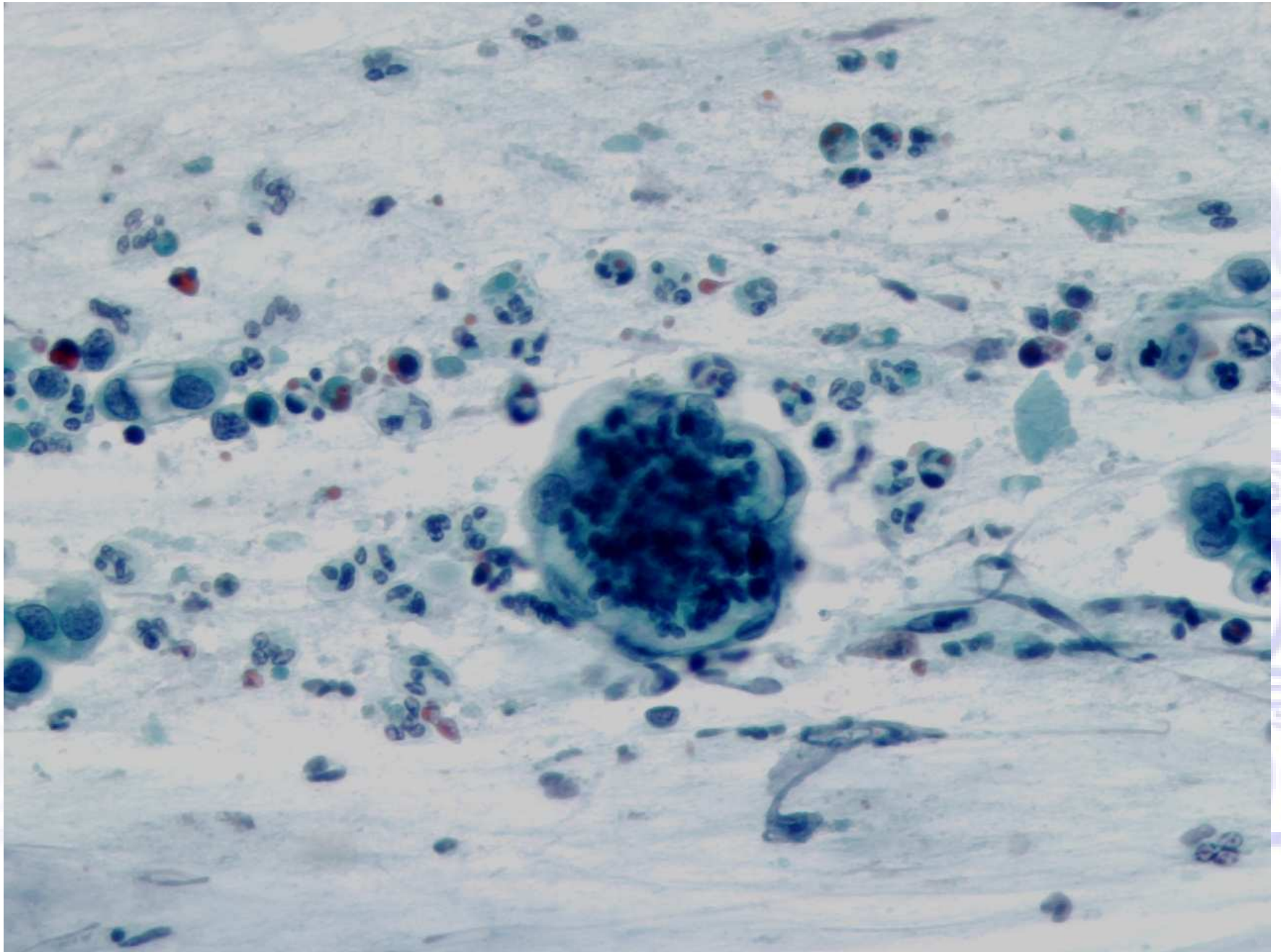
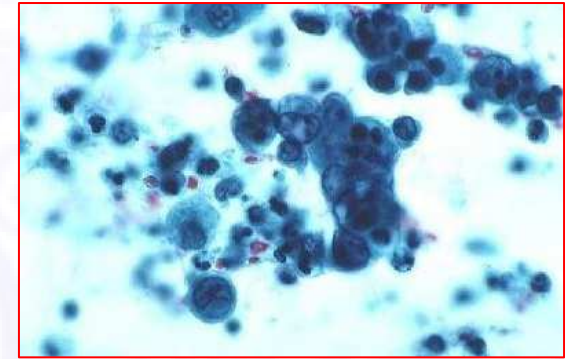


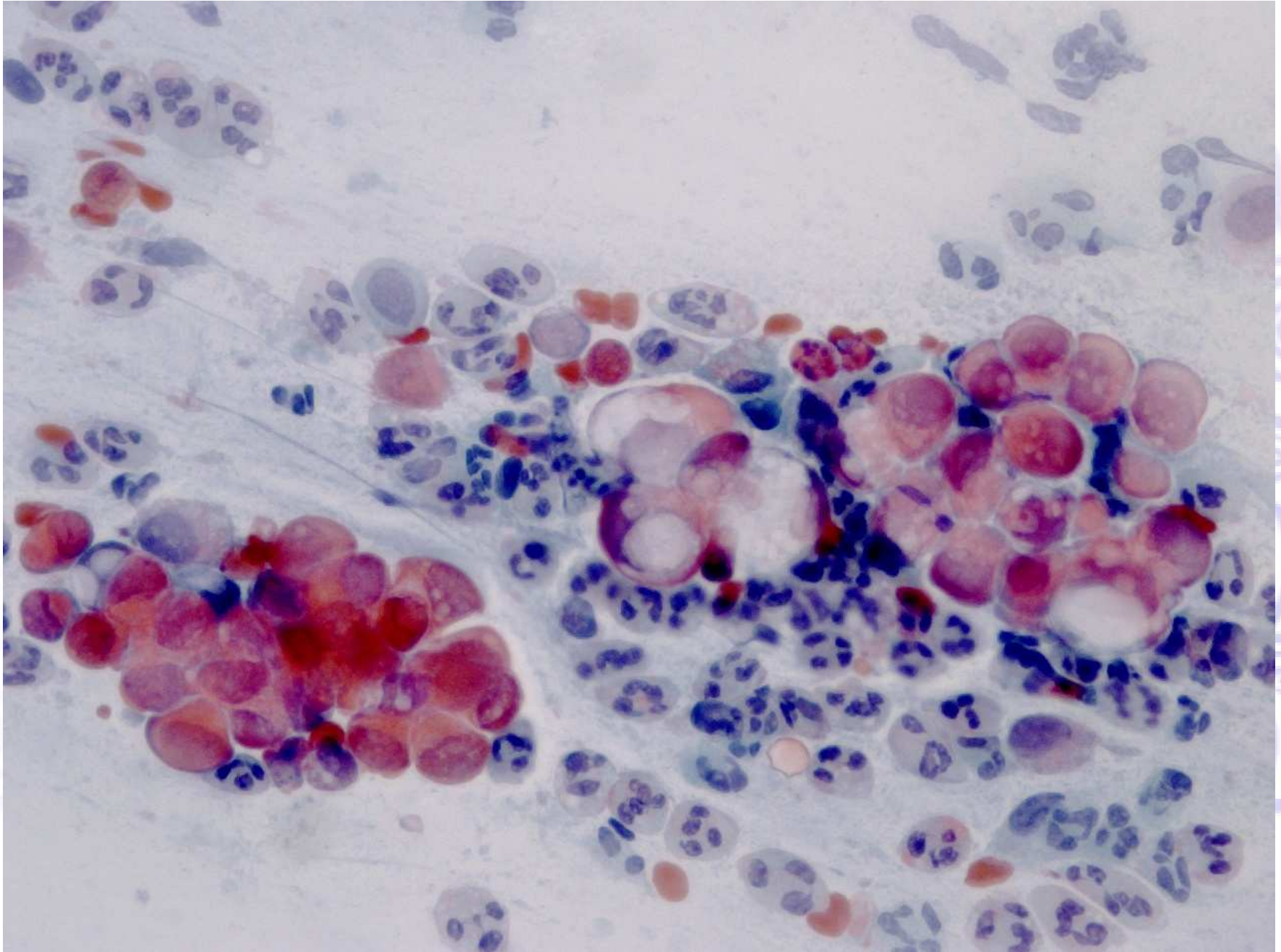
PHOTO COURTESY OF DR. J. H. WILSON

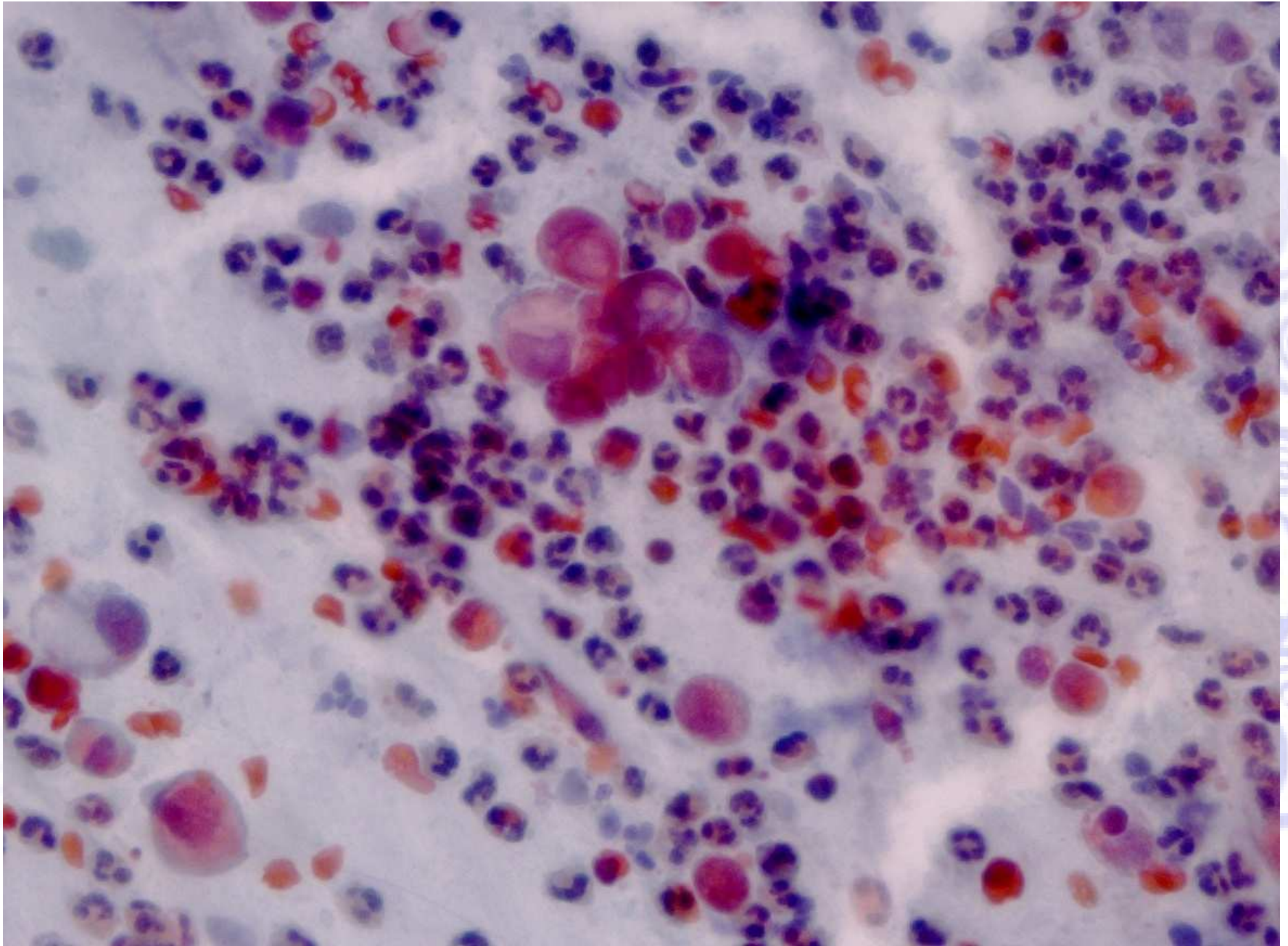
Adenocarcinoma endometriale

Criteri morfologici:

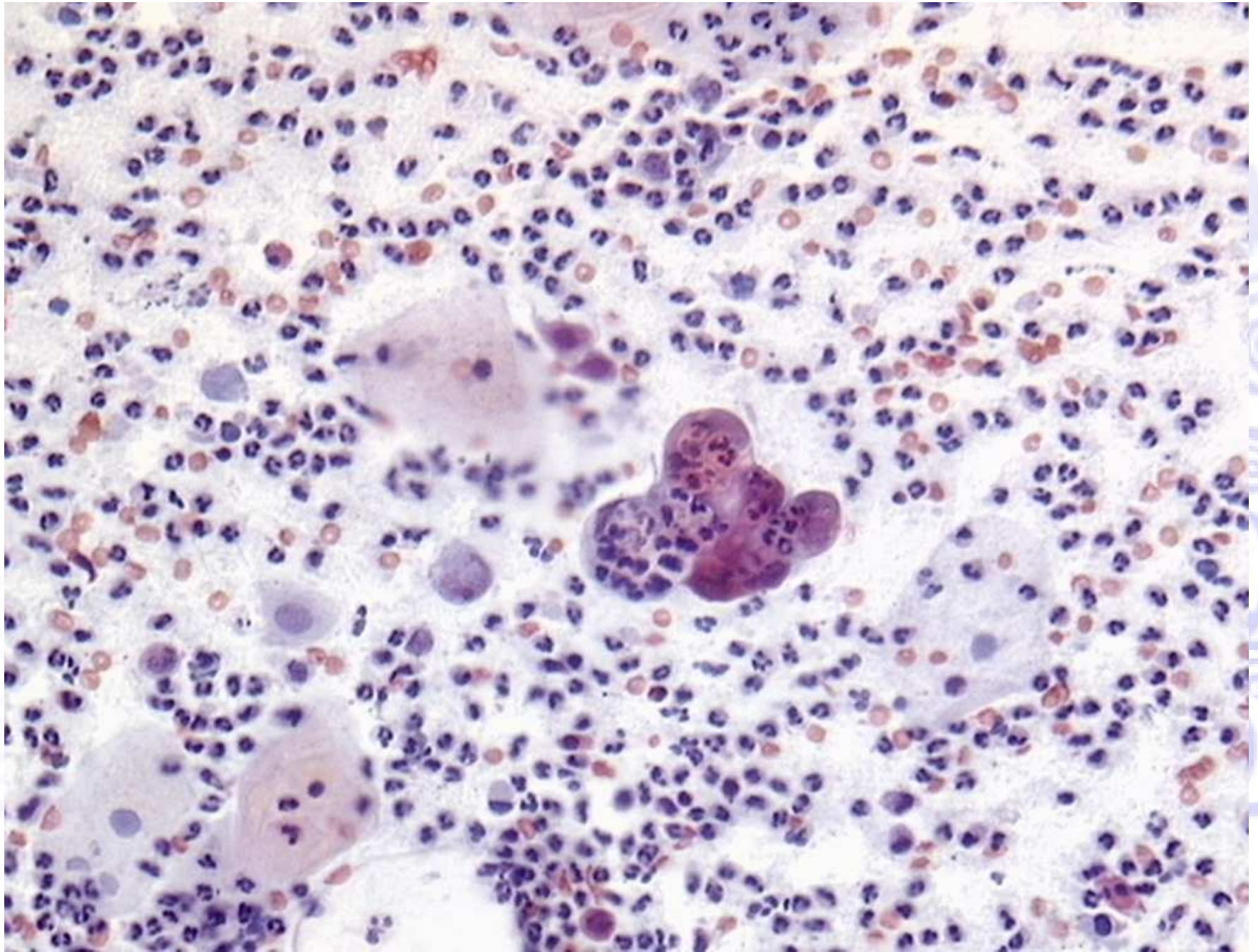
- Cellule isolate o riunite in piccoli spessi aggregati
- Nuclei ingranditi proporzionalmente al grado della neoplasia e perdita della polarità
- Nei tumori di grado più elevato, i nuclei sono moderatamente ipercromici con cromatina irregolare ed aree chiare
- I nucleoli da piccoli a prominenti (le dimensioni aumentano col grado della neoplasia)
- Il citoplasma è scarso, cianofilo, spesso vacuolizzato
- Neutrofili intracitoplasmatici sono comuni
- Può essere presente diatesi tumorale finemente granulare o “acquosa”



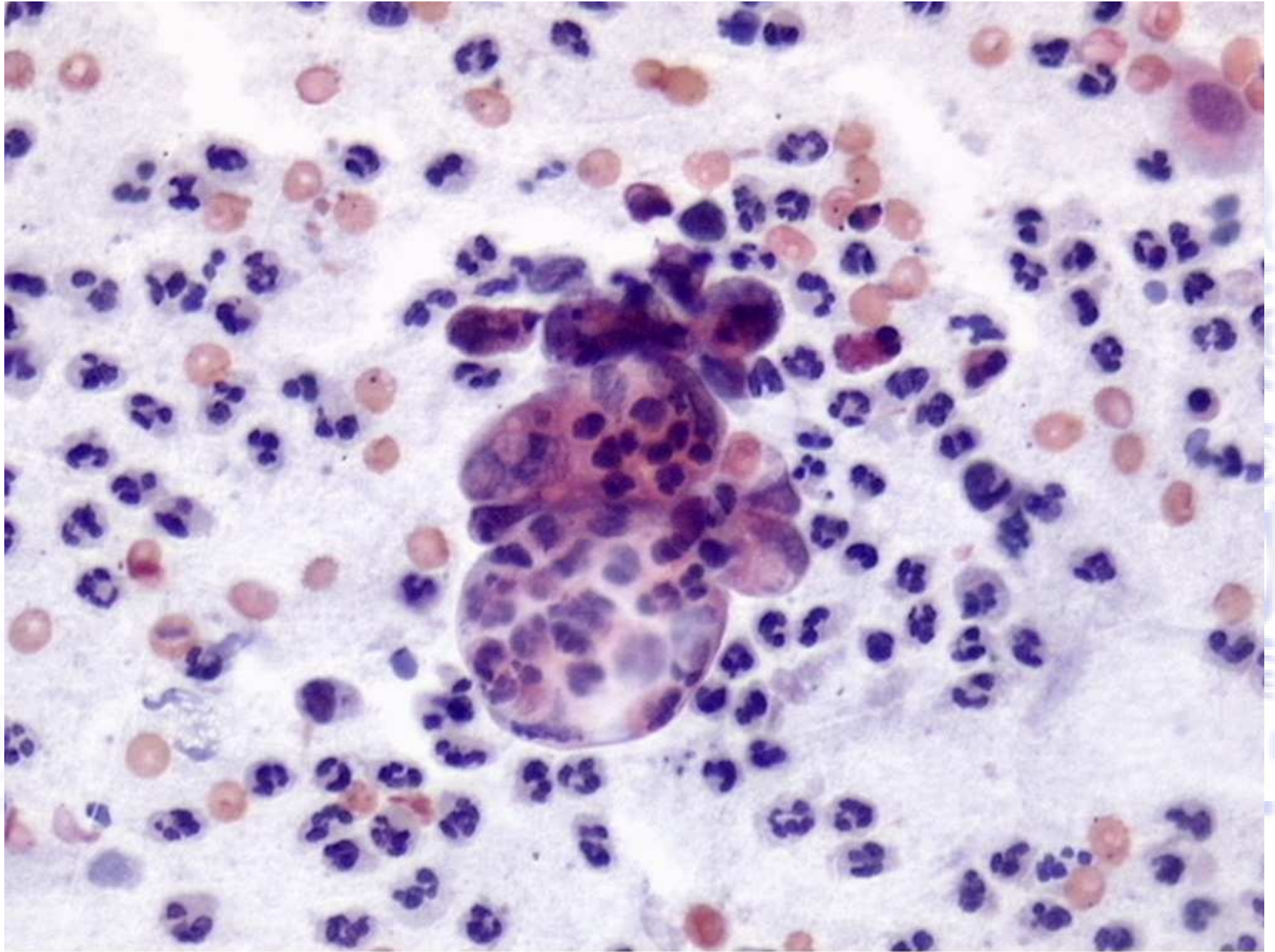


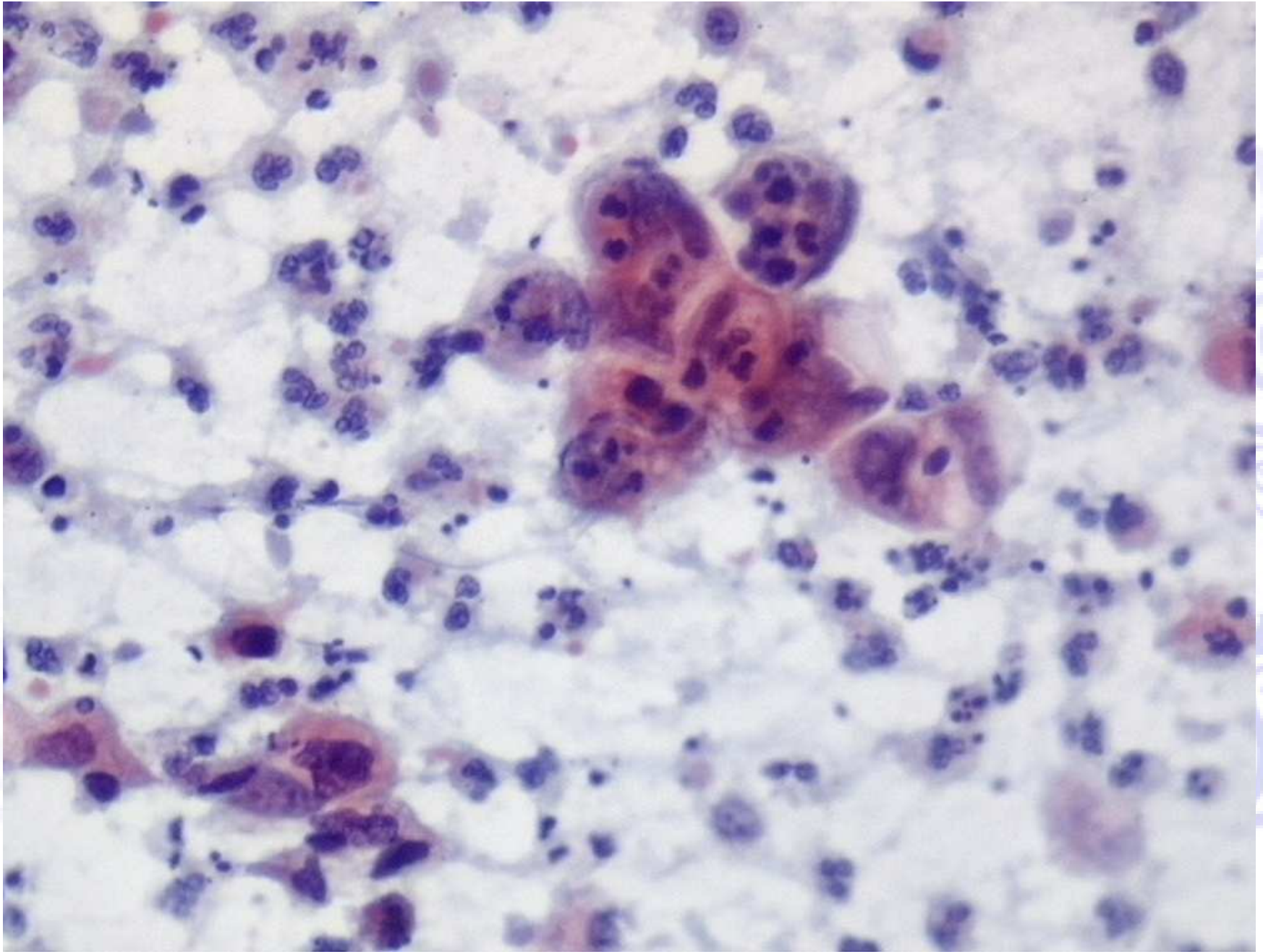


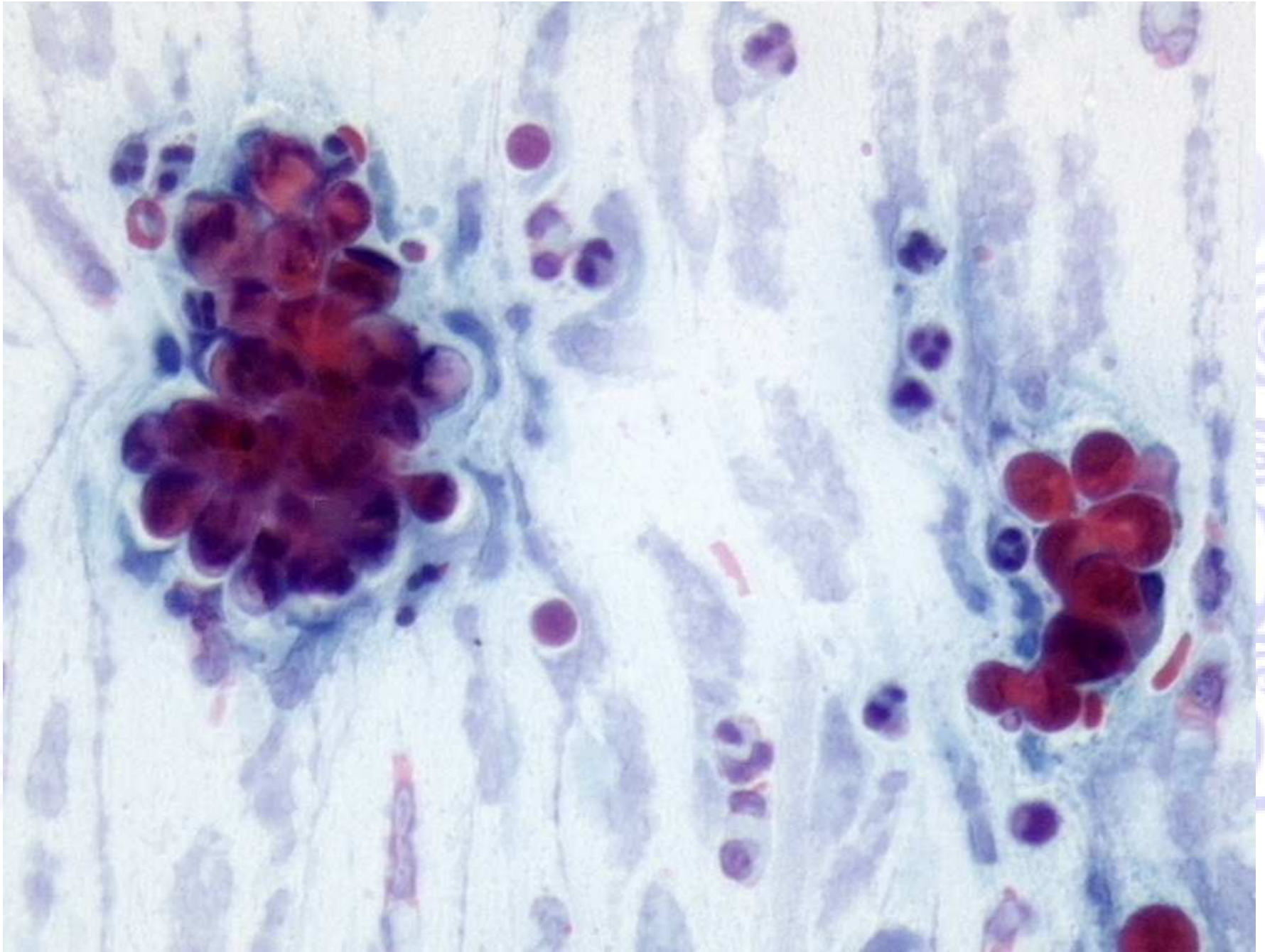
Copyright © 2010 Wolters Kluwer Health | Lippincott Williams & Wilkins



UNIVERSITY OF SAUDI MEDICAL SCIENCES

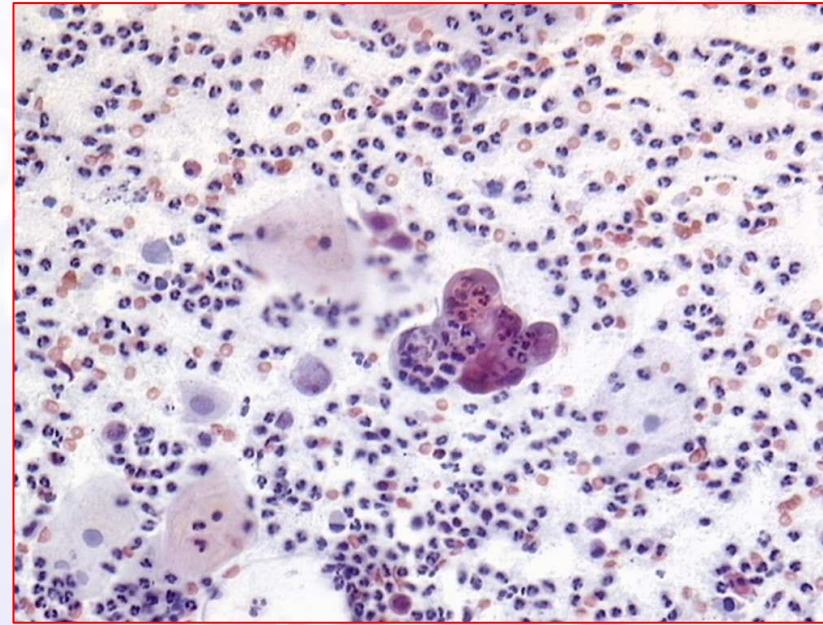
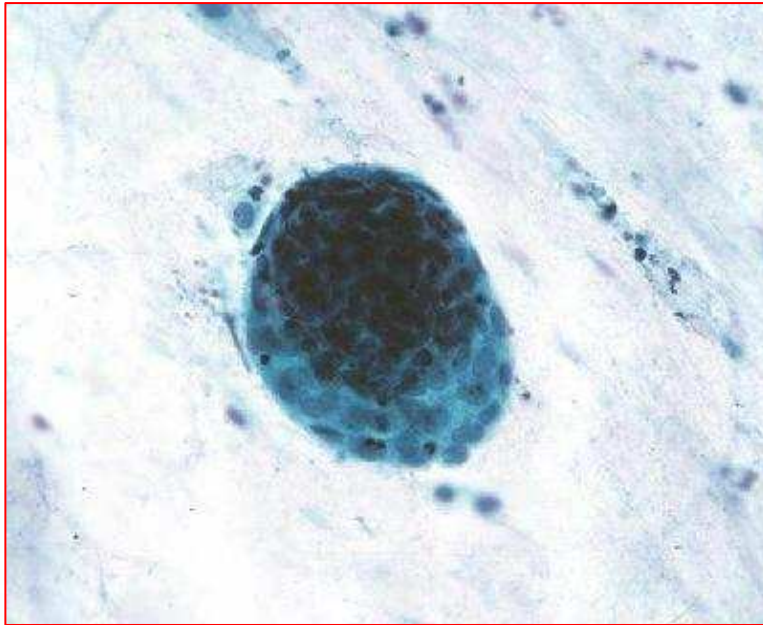




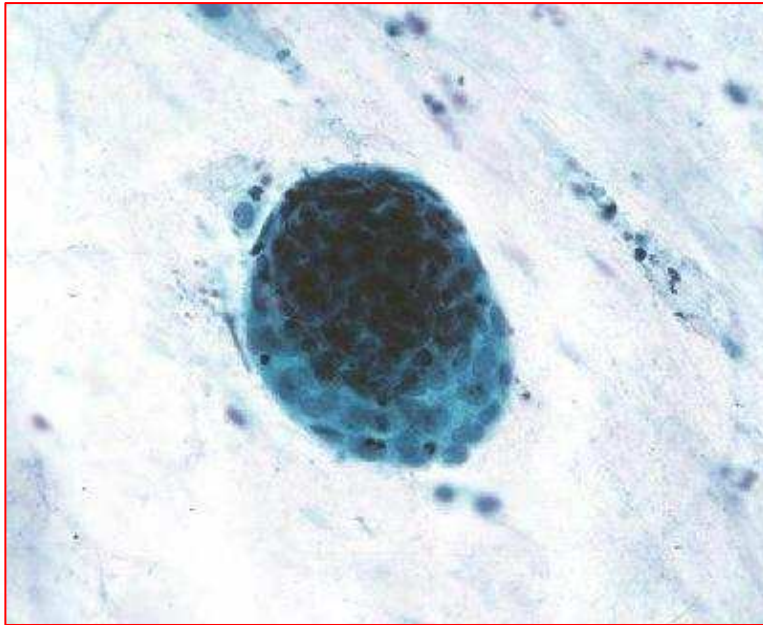


© 2011 Pearson Education, Inc. All rights reserved. This material is protected by copyright. No part of this material may be reproduced, stored, or transmitted in any form or by any means without the prior written permission of Pearson Education, Inc.

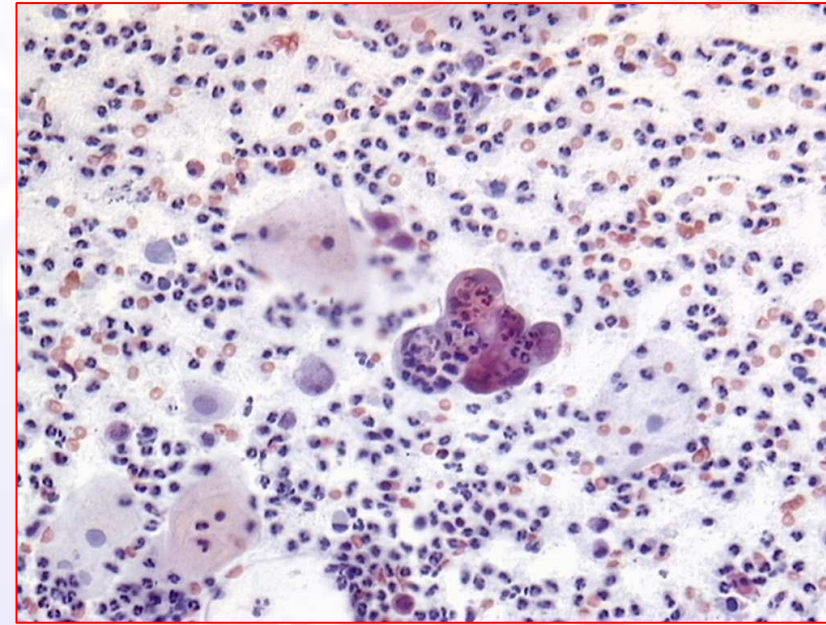
Quiz



Quiz



Exodus



**Adenocarcinoma
Endometriale**




CRITICITA'

Diagnosi citologica di adenocarcinoma



Tipo di campionamento

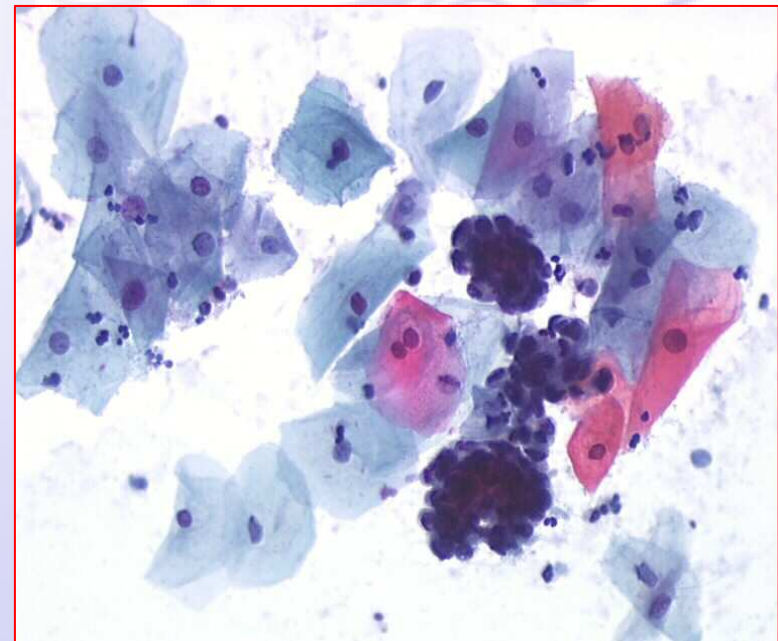
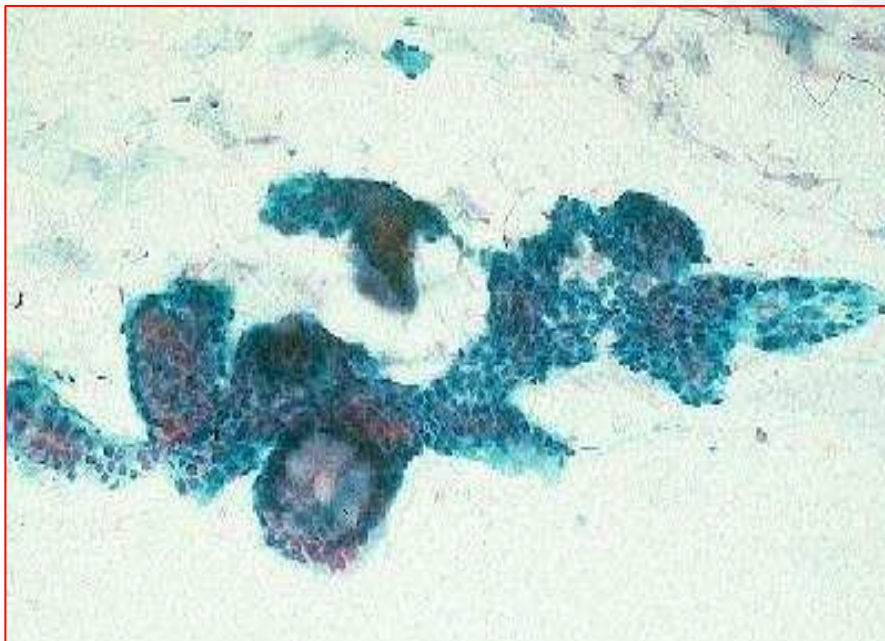


Problemi di interpretazione

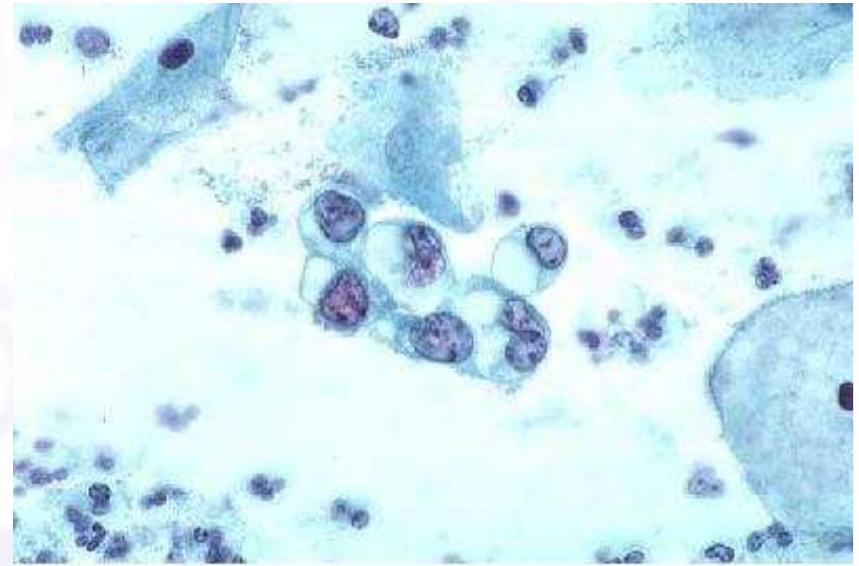
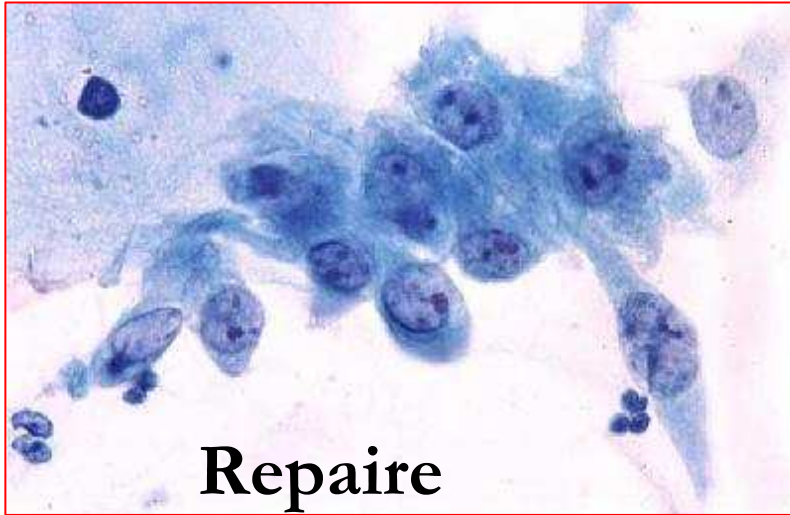Tipo di campionamento

Artefatti dovuti al brushing, soprattutto se energico:

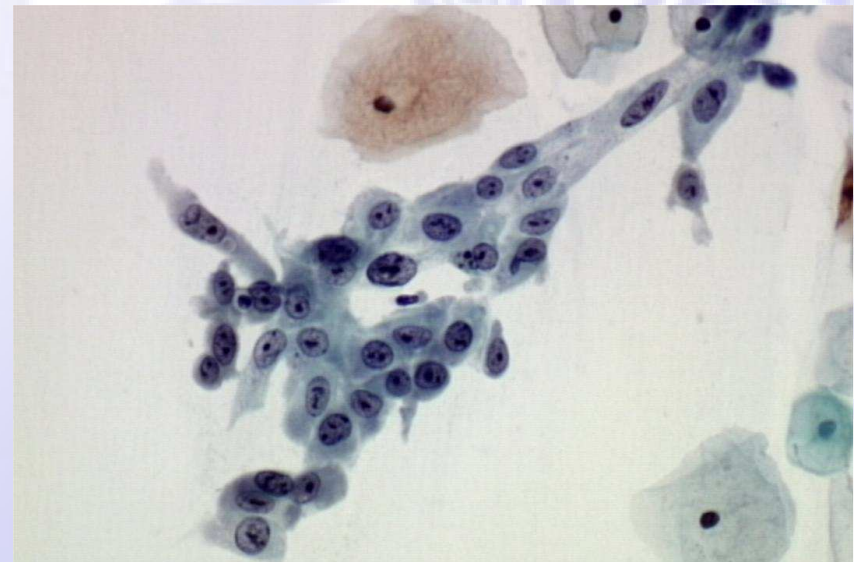
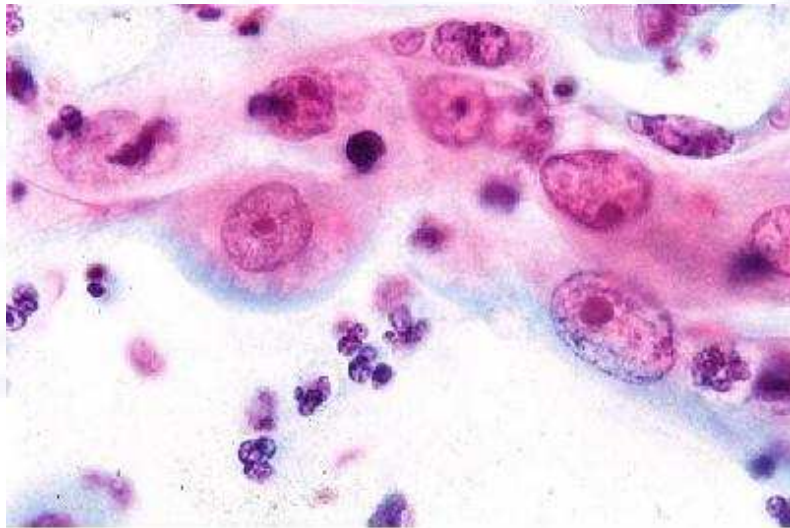- presenza di spessi aggregati di cellule endocervicali con contorni irregolari e “feathering”, che possono mimare le atipie dell’adenocarcinoma
- presenza di cellule endometriali (in assenza di notizie cliniche)



Problemi di interpretazione



IUD





Follow-up delle lesioni ghiandolari


Le atipie ghiandolari dovrebbero essere classificate con riferimento al tipo cellulare d'origine, poiché le indagini cliniche ed il trattamento delle pazienti variano significativamente a seconda del tipo di lesione, se endocervicale o endometriale

A microscopic image showing a dense cluster of cells, likely a tumor or a specific tissue sample, stained with a purple dye. The cells are irregular in shape and densely packed together. The background is a light, slightly textured surface.

Grazie

Giuditta Ori

Prassede Foxi



Grazie per l'attenzione